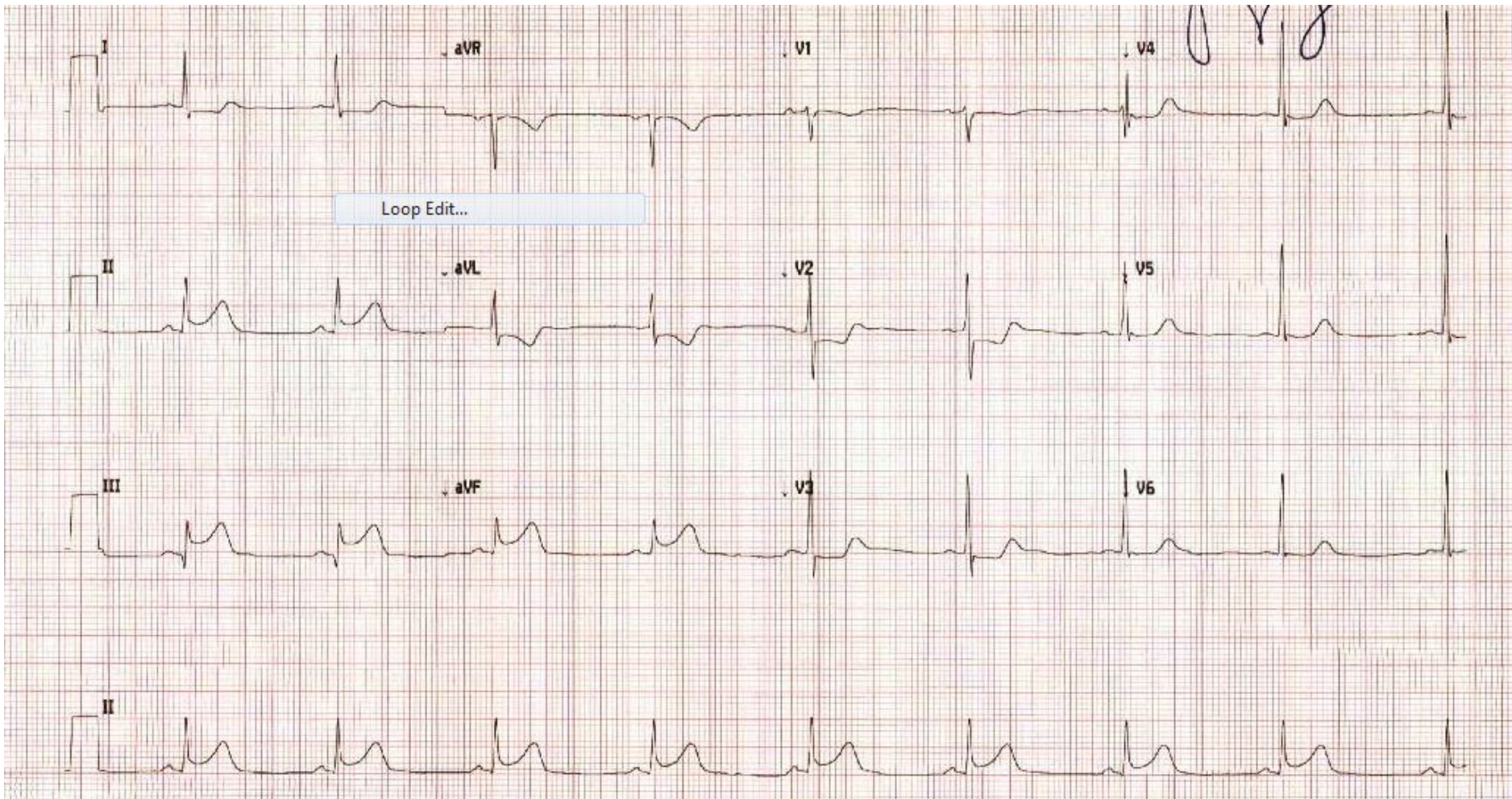
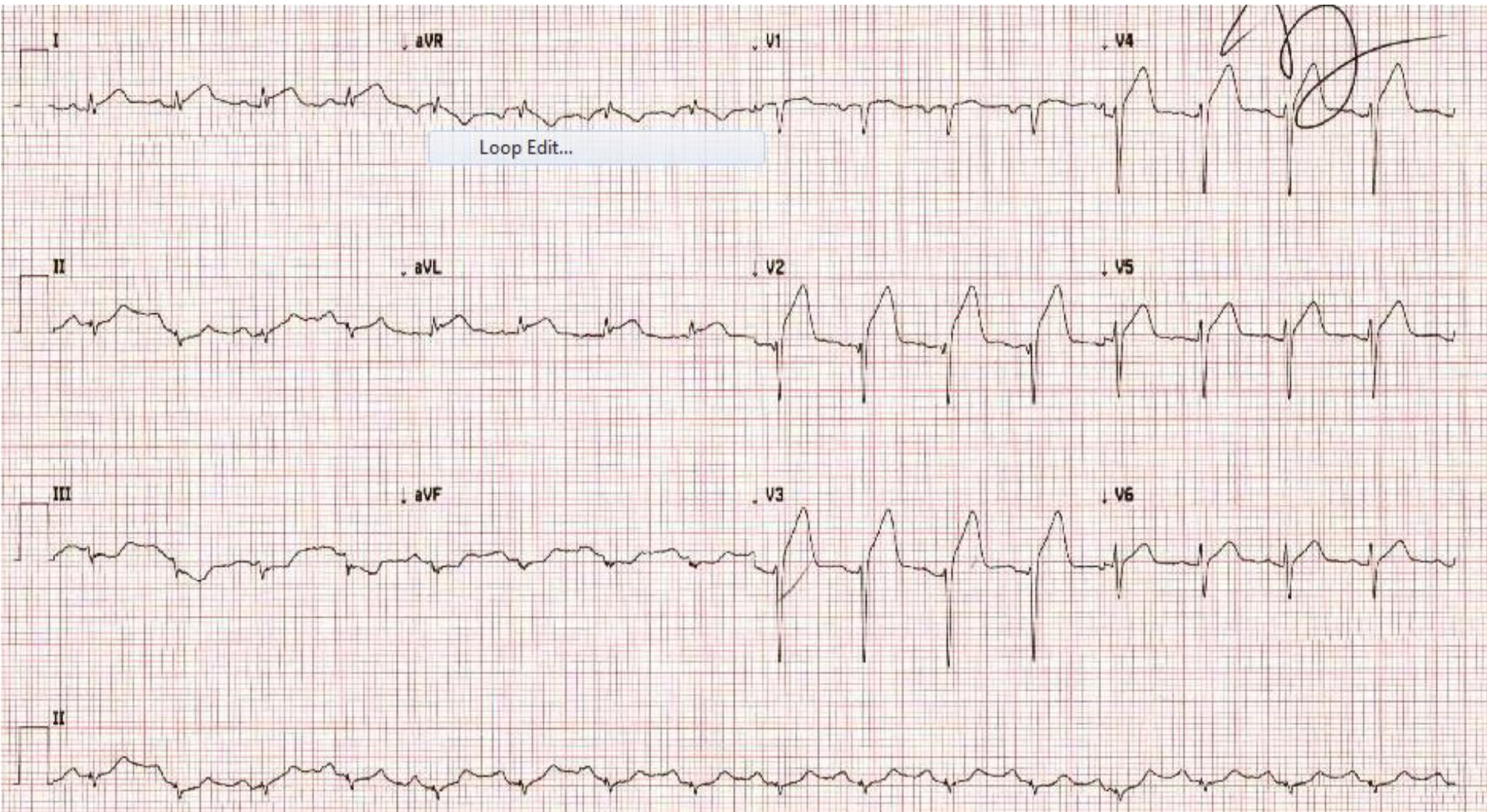


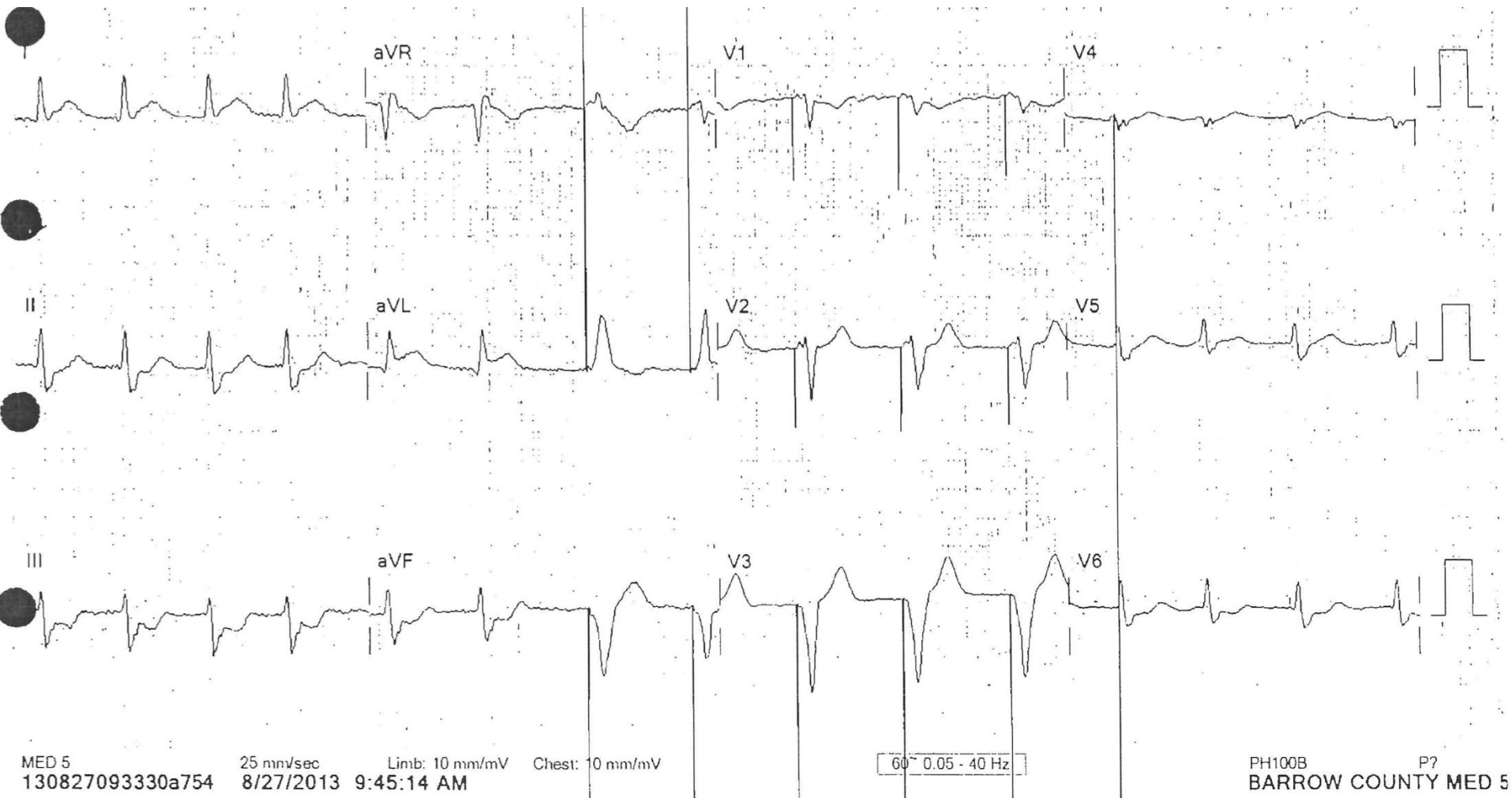
54 year old male, HTN, HLD, DM, tobacco abuse with one hour of chest pain



55 year old male with no medical history with one hour of crushing substernal chest pain



83 year old male with no medical history with one hour of crushing substernal chest pain

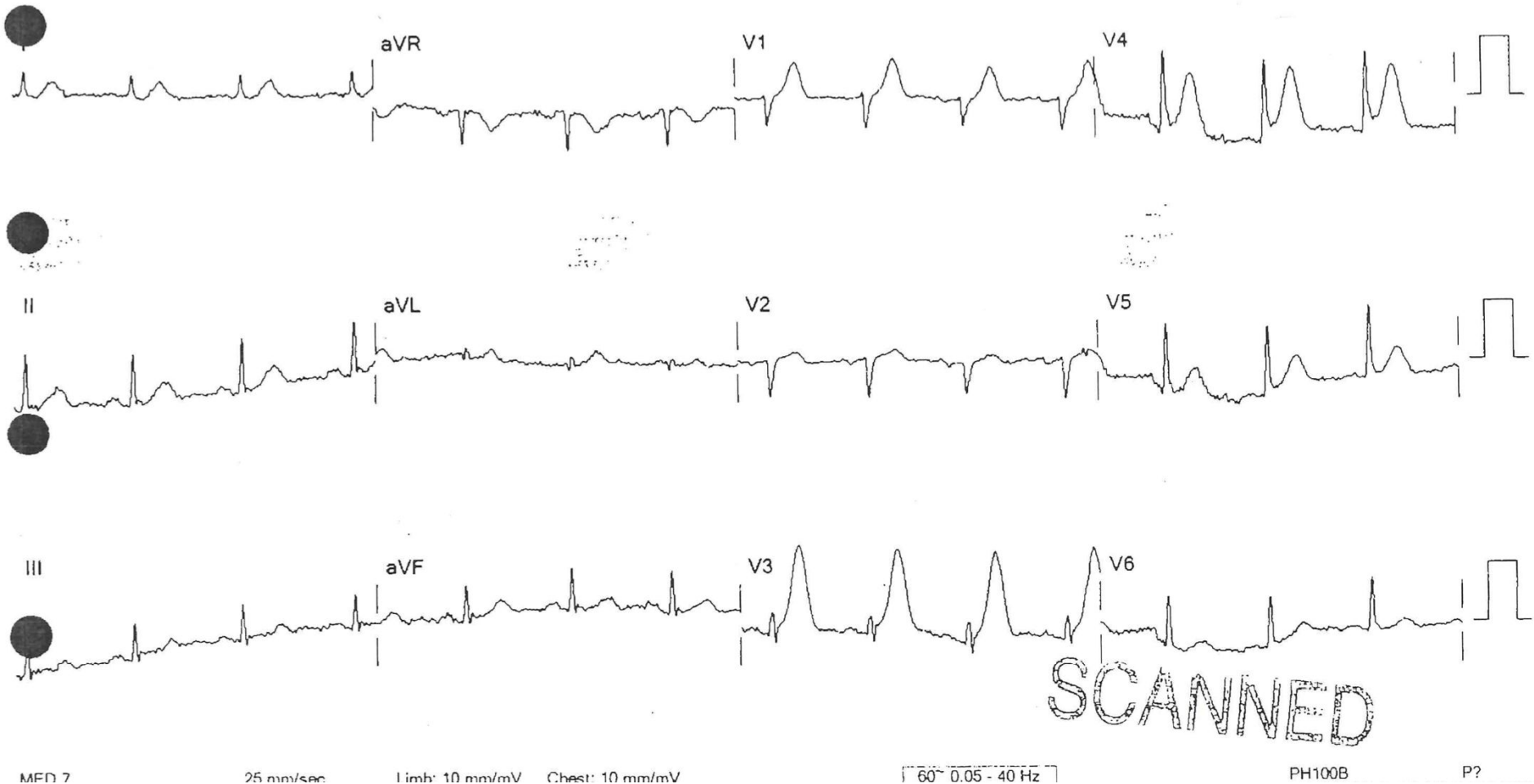


4A



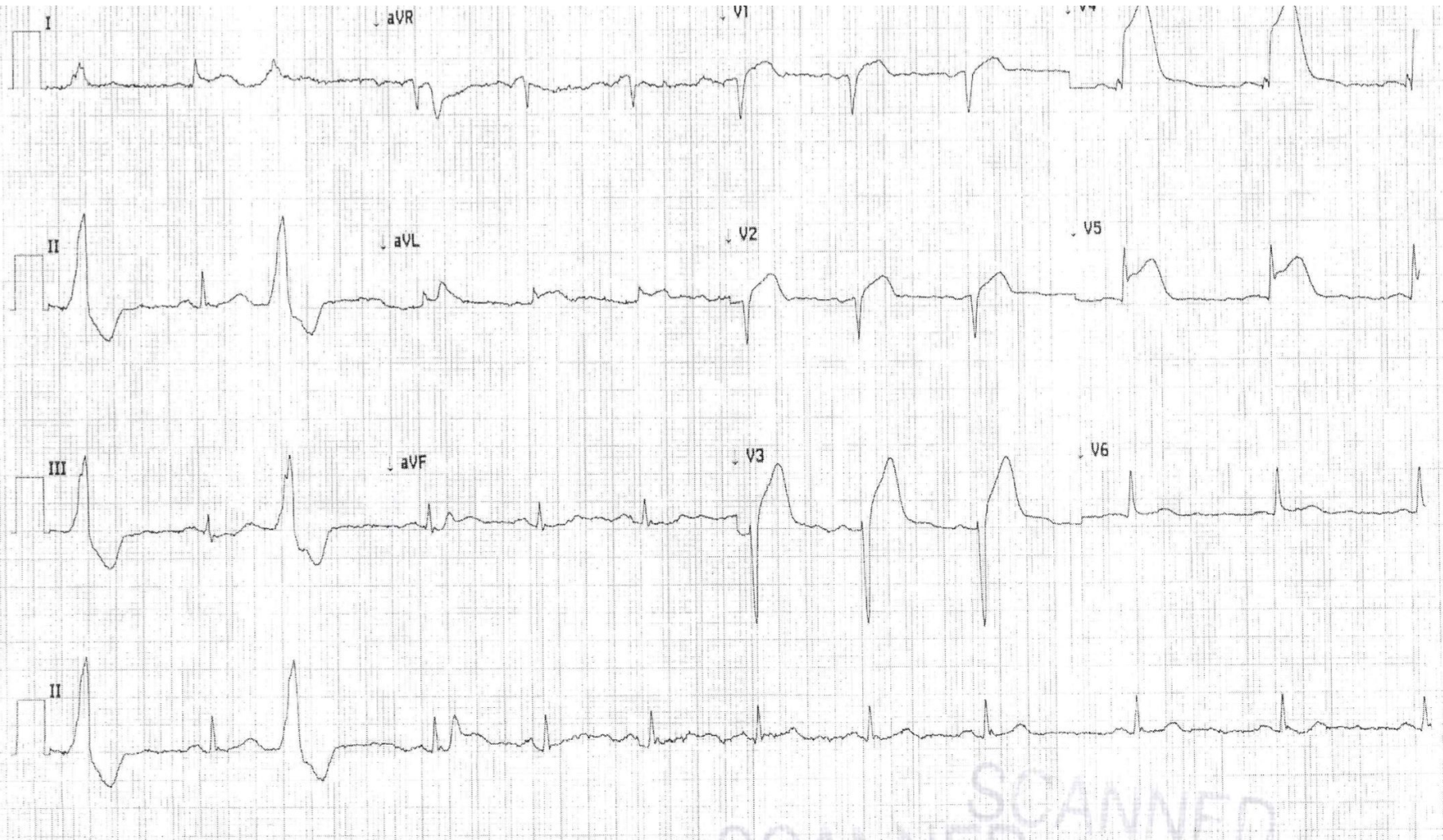
45 year old male with tobacco abuse, 40 minutes
after crushing chest pain at rest

4B

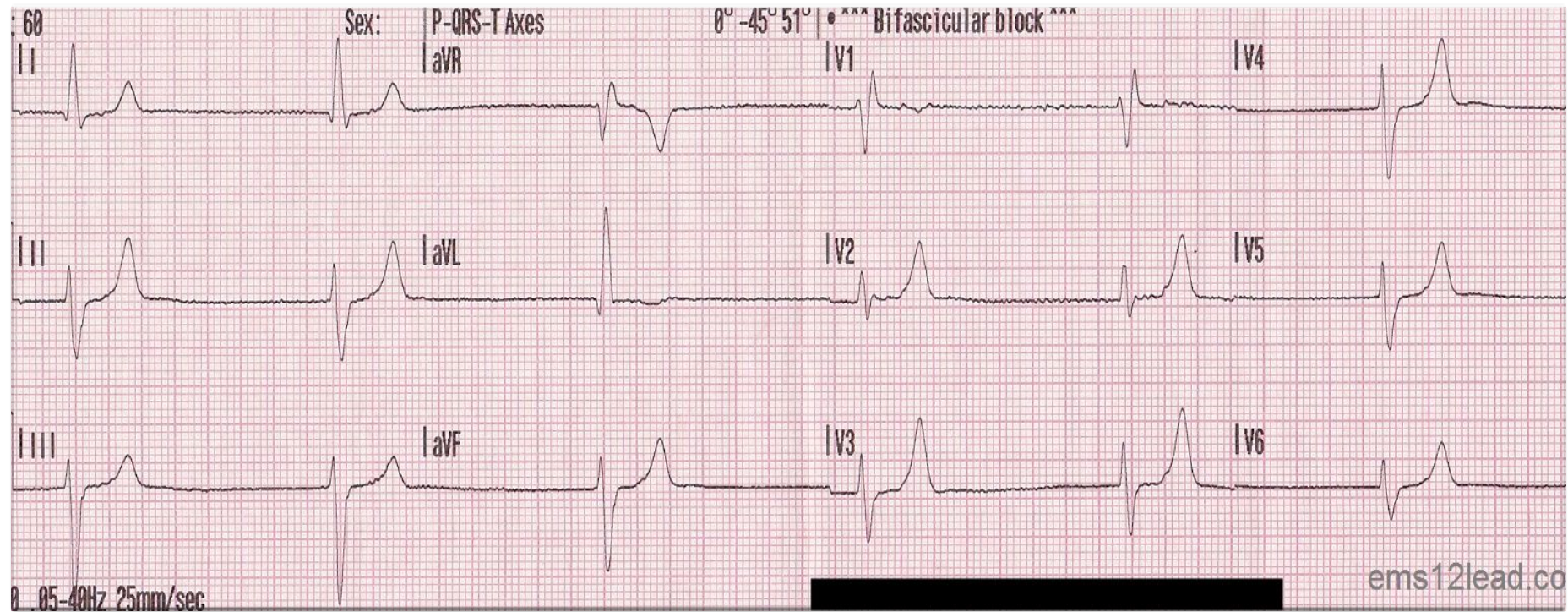


45 year old male with tobacco abuse, 50 minutes
after crushing chest pain at rest

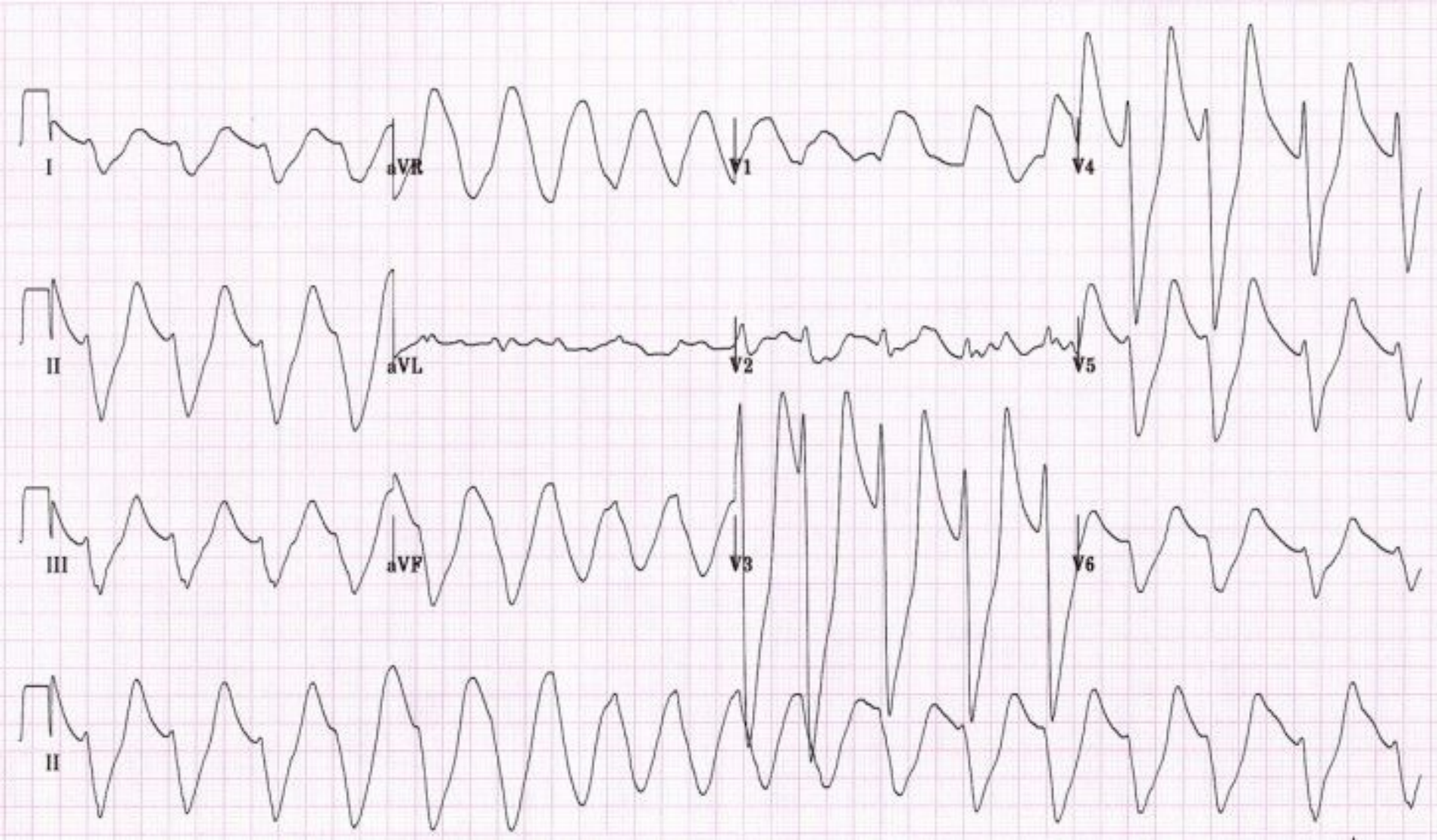
4C



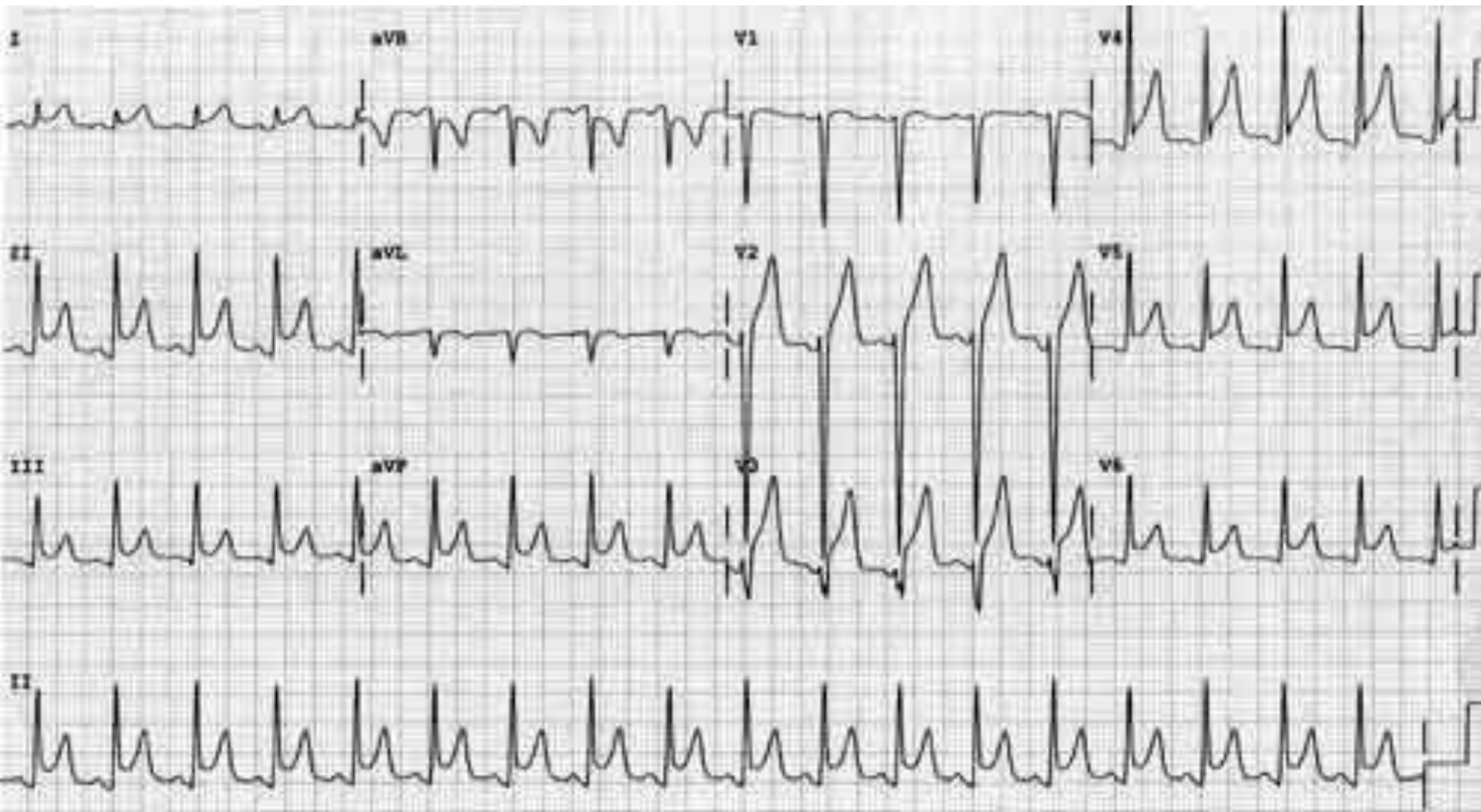
60 year old male with HTN started on new BP med, spironolactone, one week ago



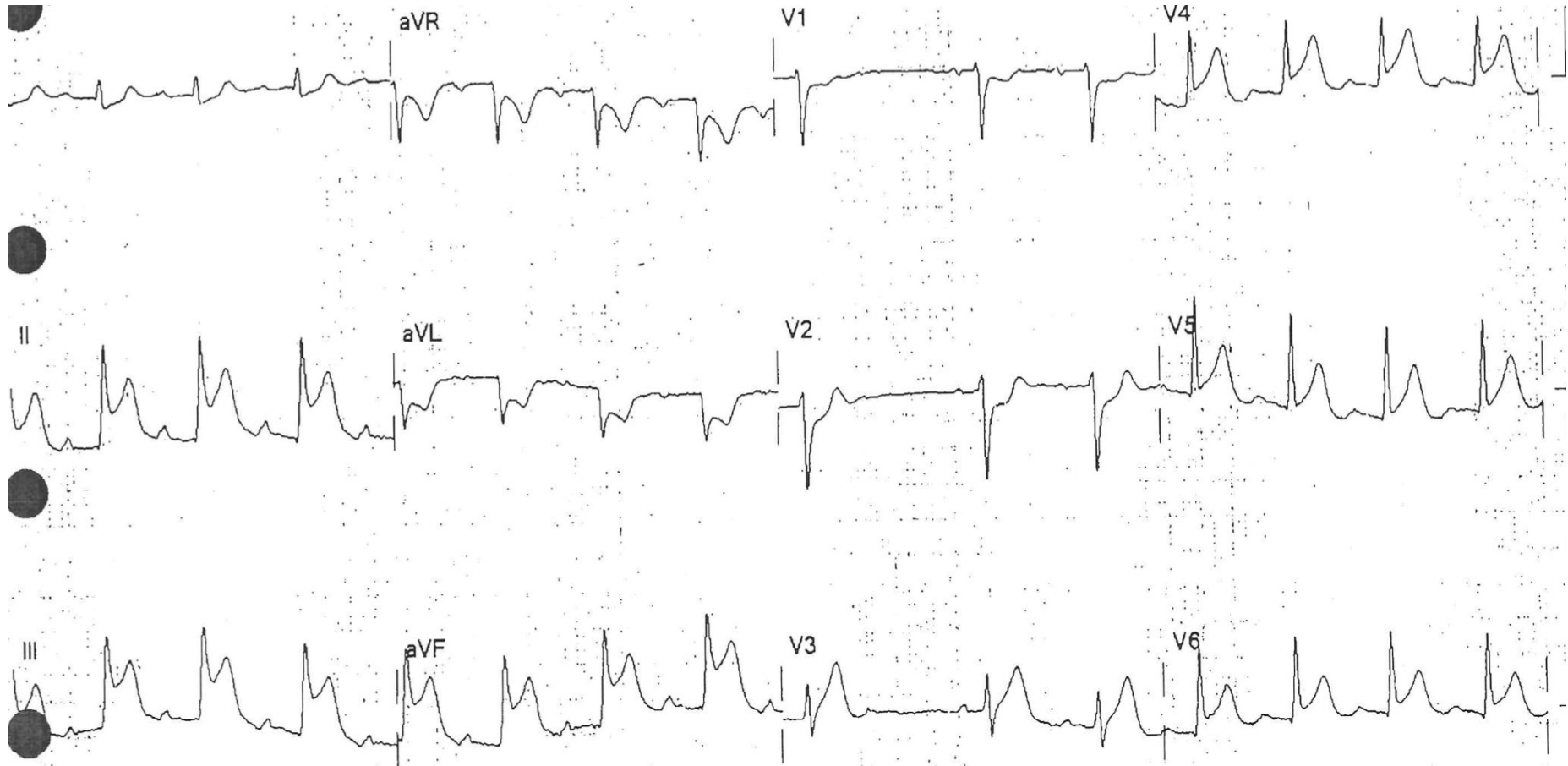
65 year old male, missed dialysis for a week, stopped taking BP meds



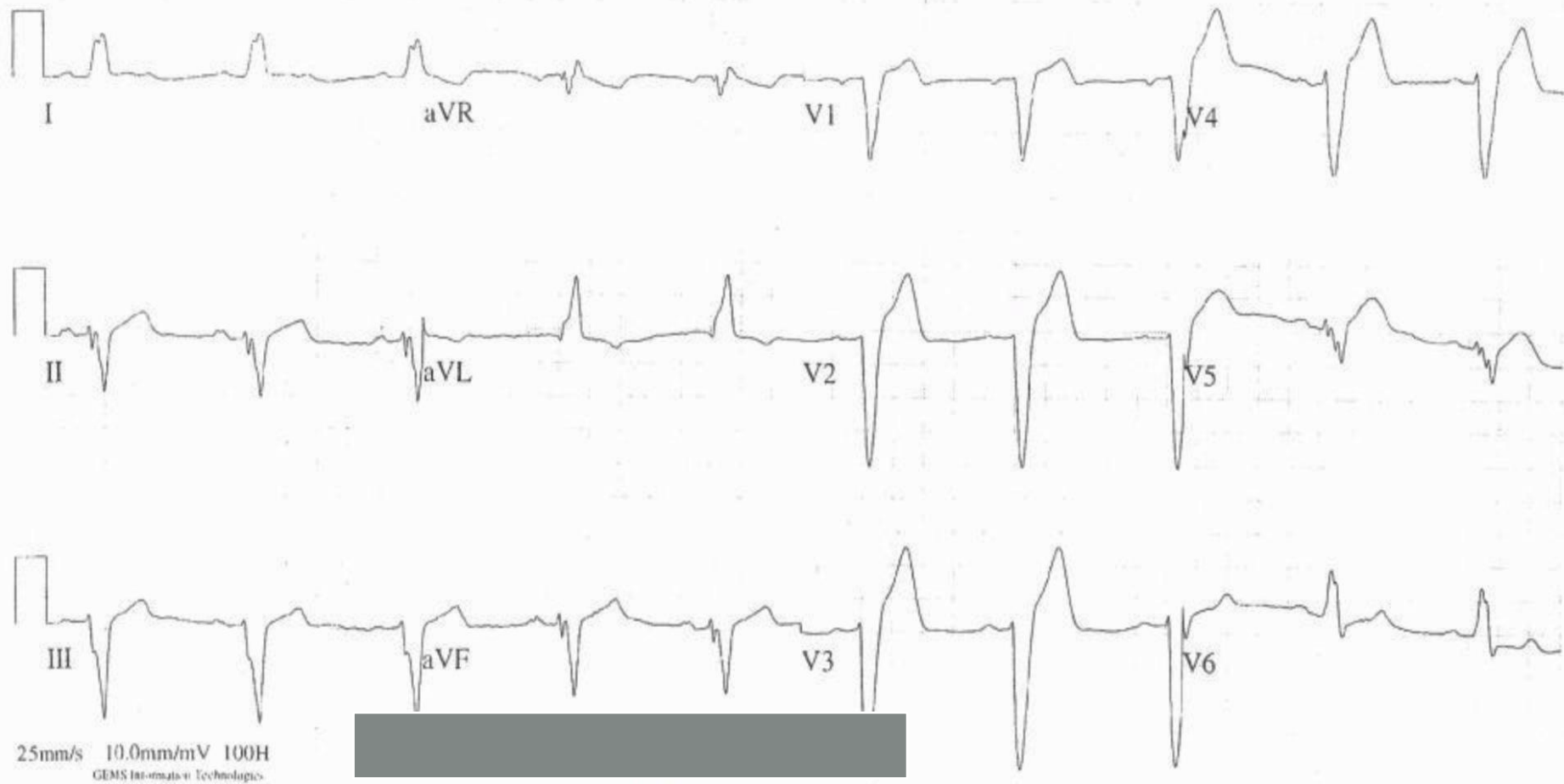
60 year old male, hours of chest pain, some chills,
better with sitting up



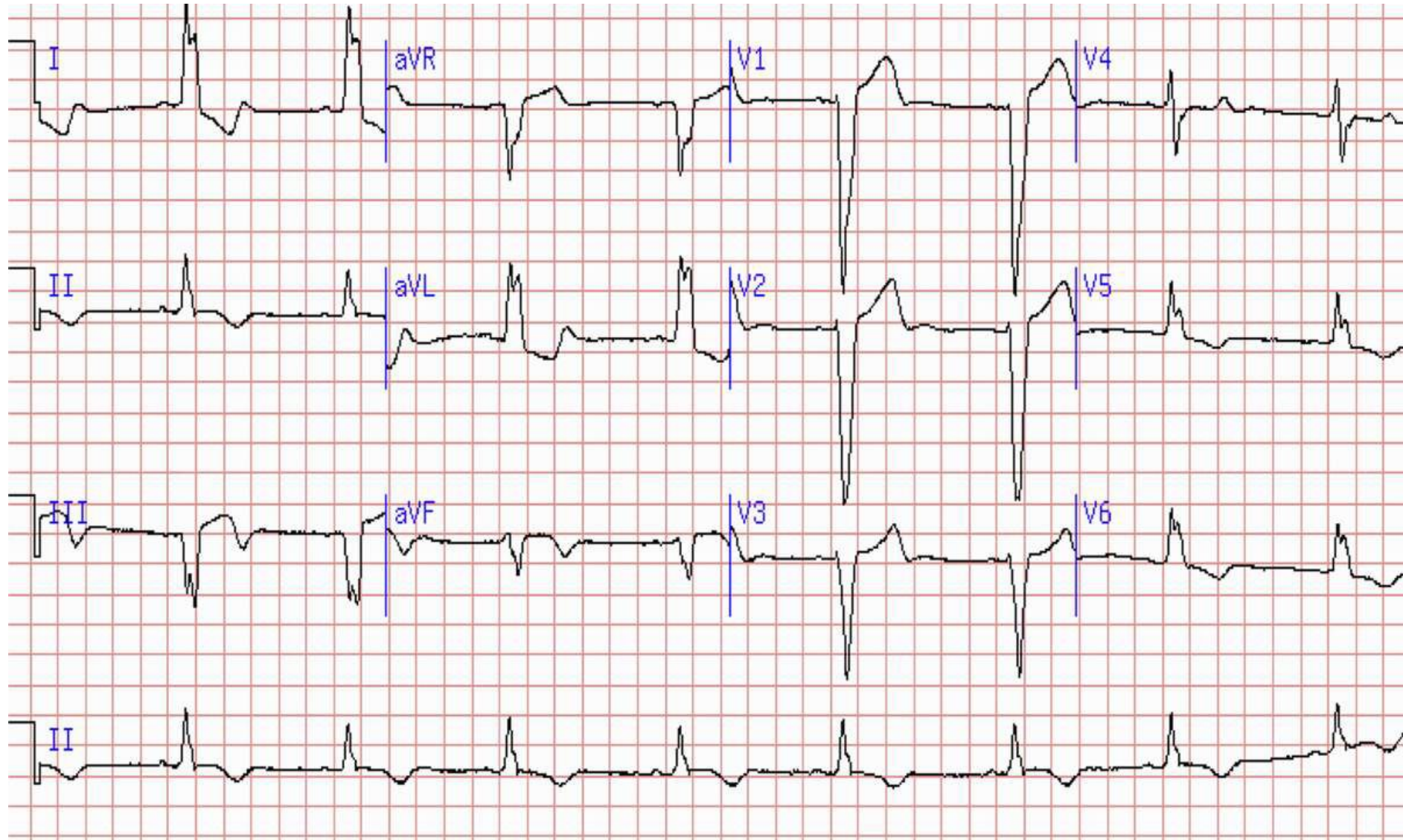
68 year old male, HTN, tobacco use, with chest pain and diaphoresis for two hours



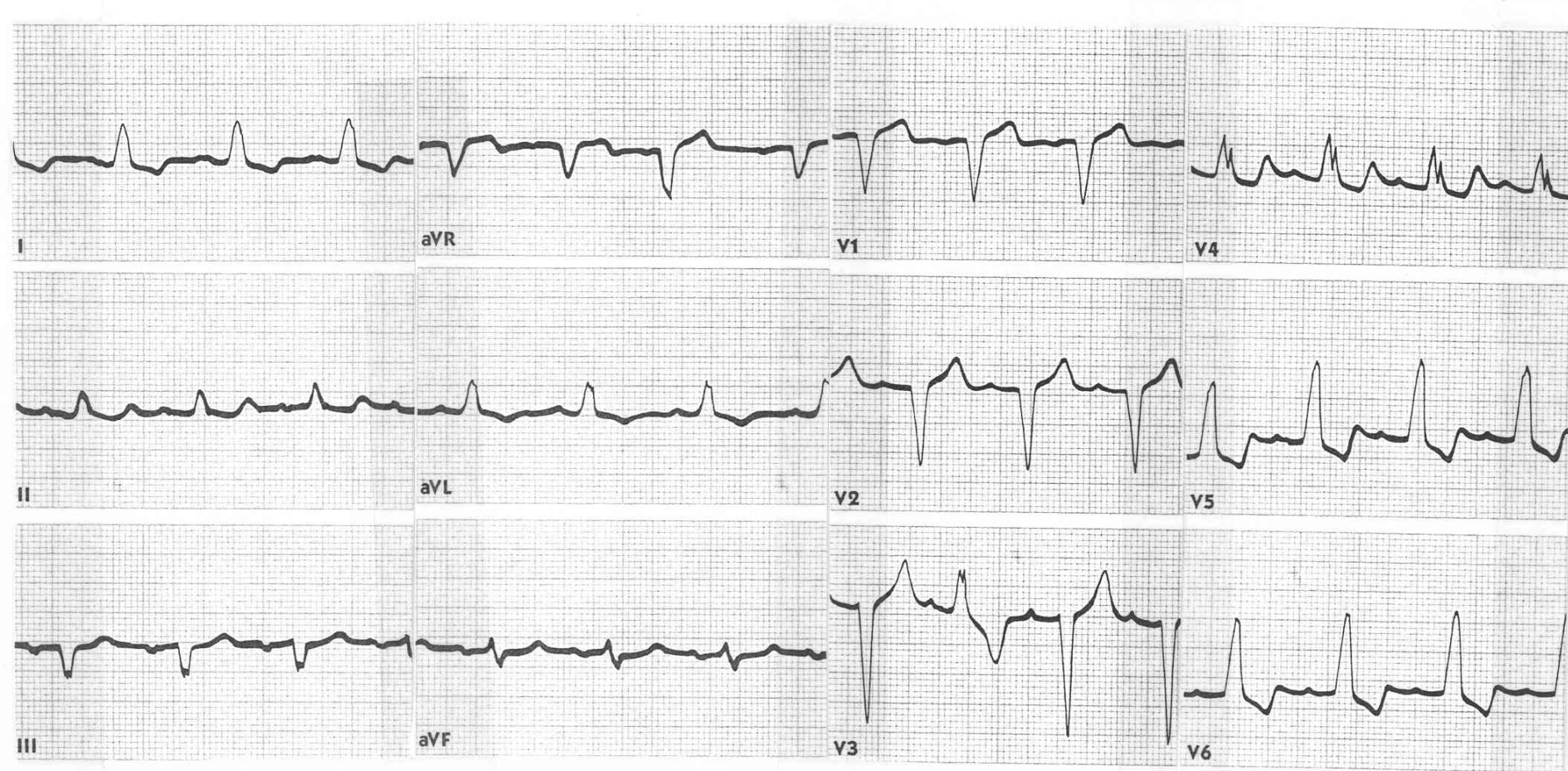
54 year old male, HTN, HLD, DM, tobacco abuse with one hour of chest pain



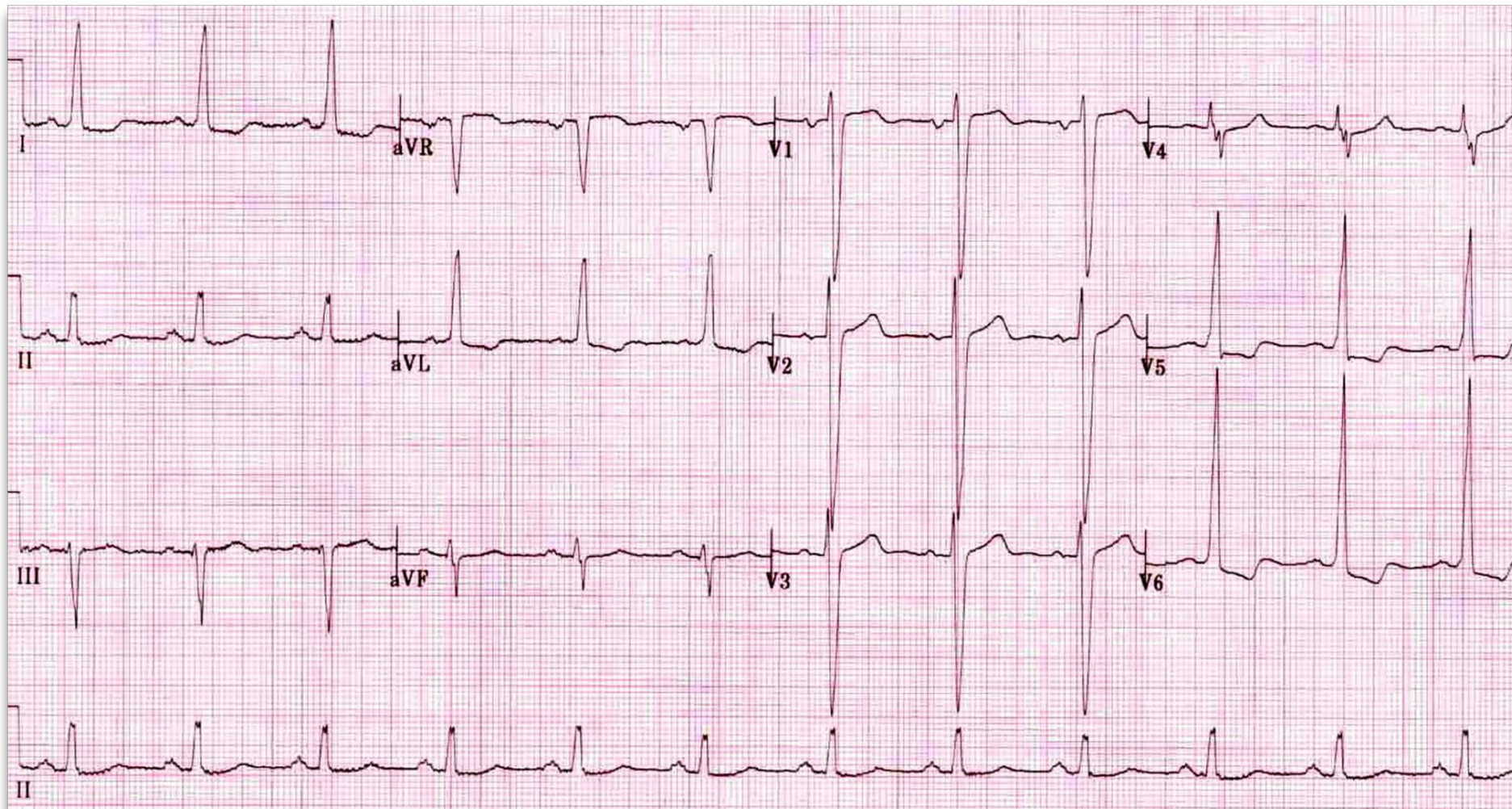
72 year old male, known LBBB, with one hour of crushing chest, dyspnea



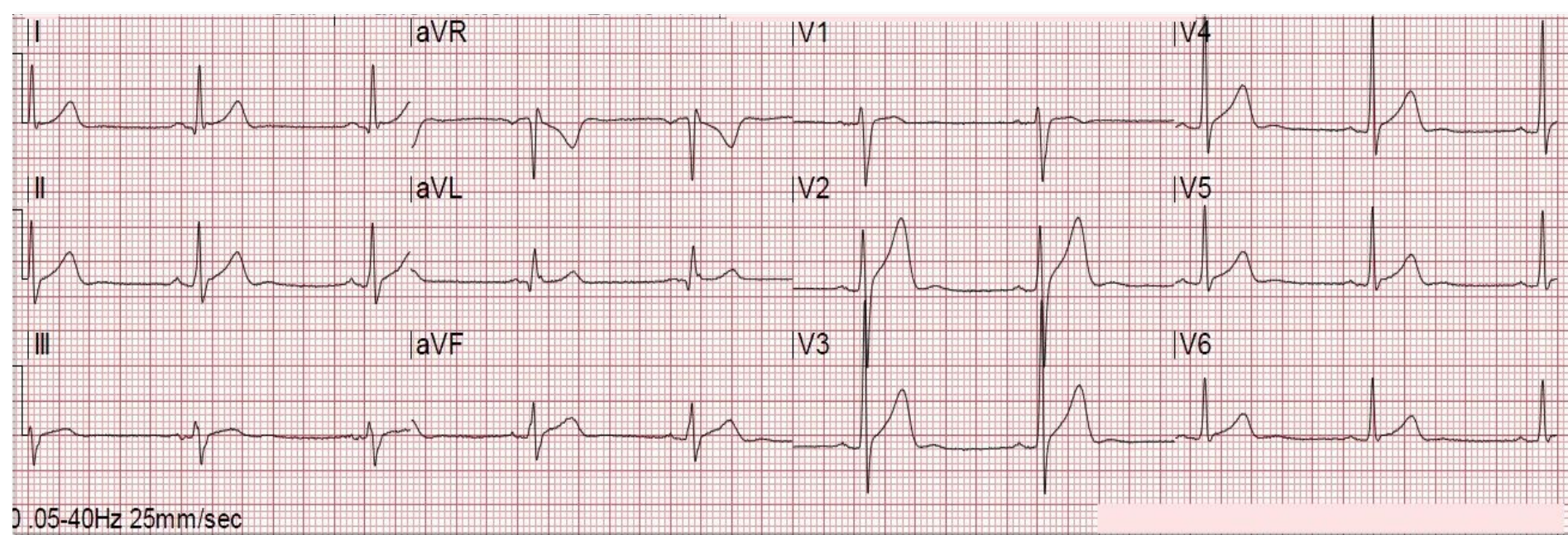
60 year old female with history of non-ischemic cardiomyopathy, mild chest pain lasting six hours



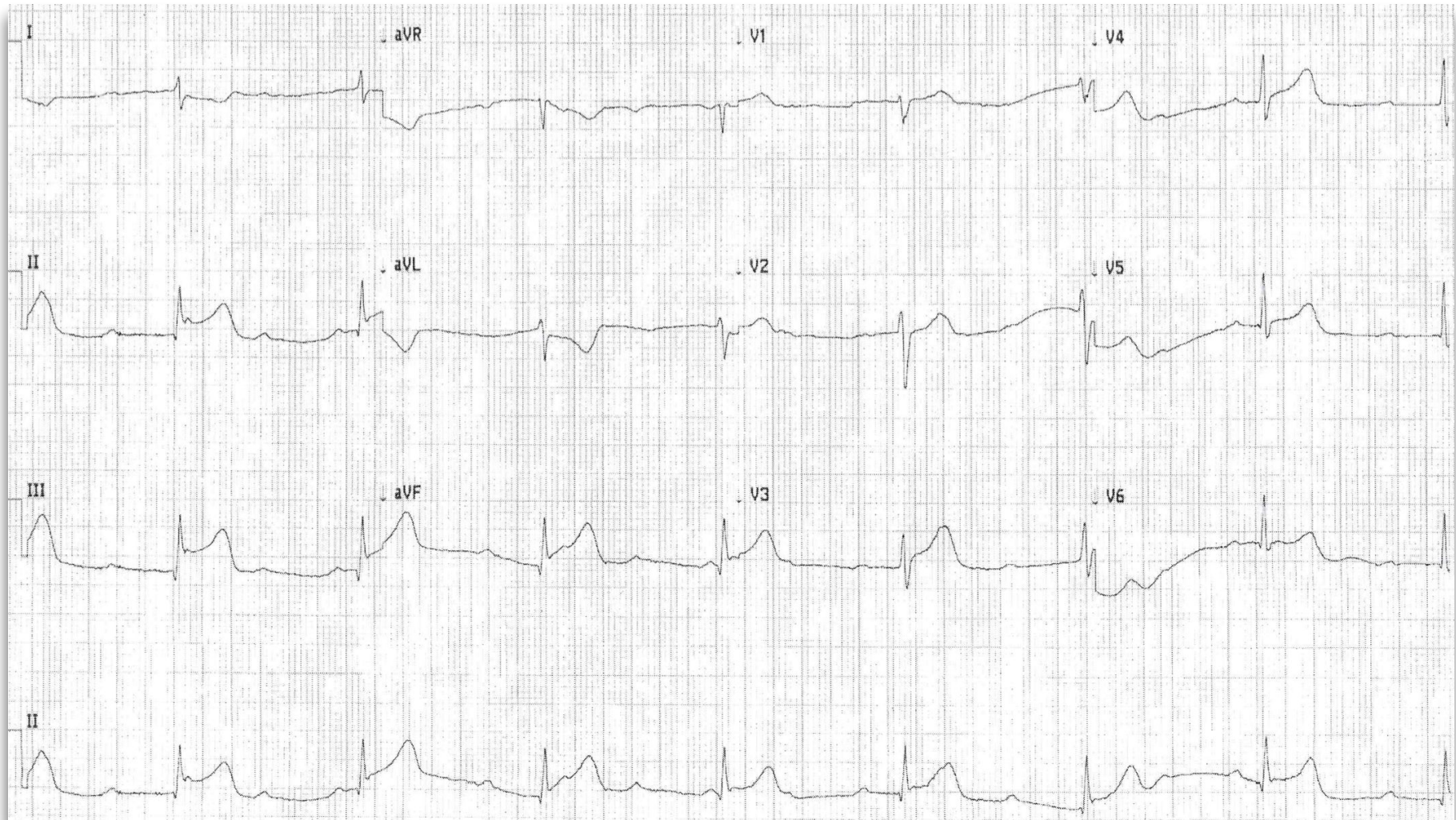
57 year old male, long standing hypertension, chest pain for a day, ran out of meds



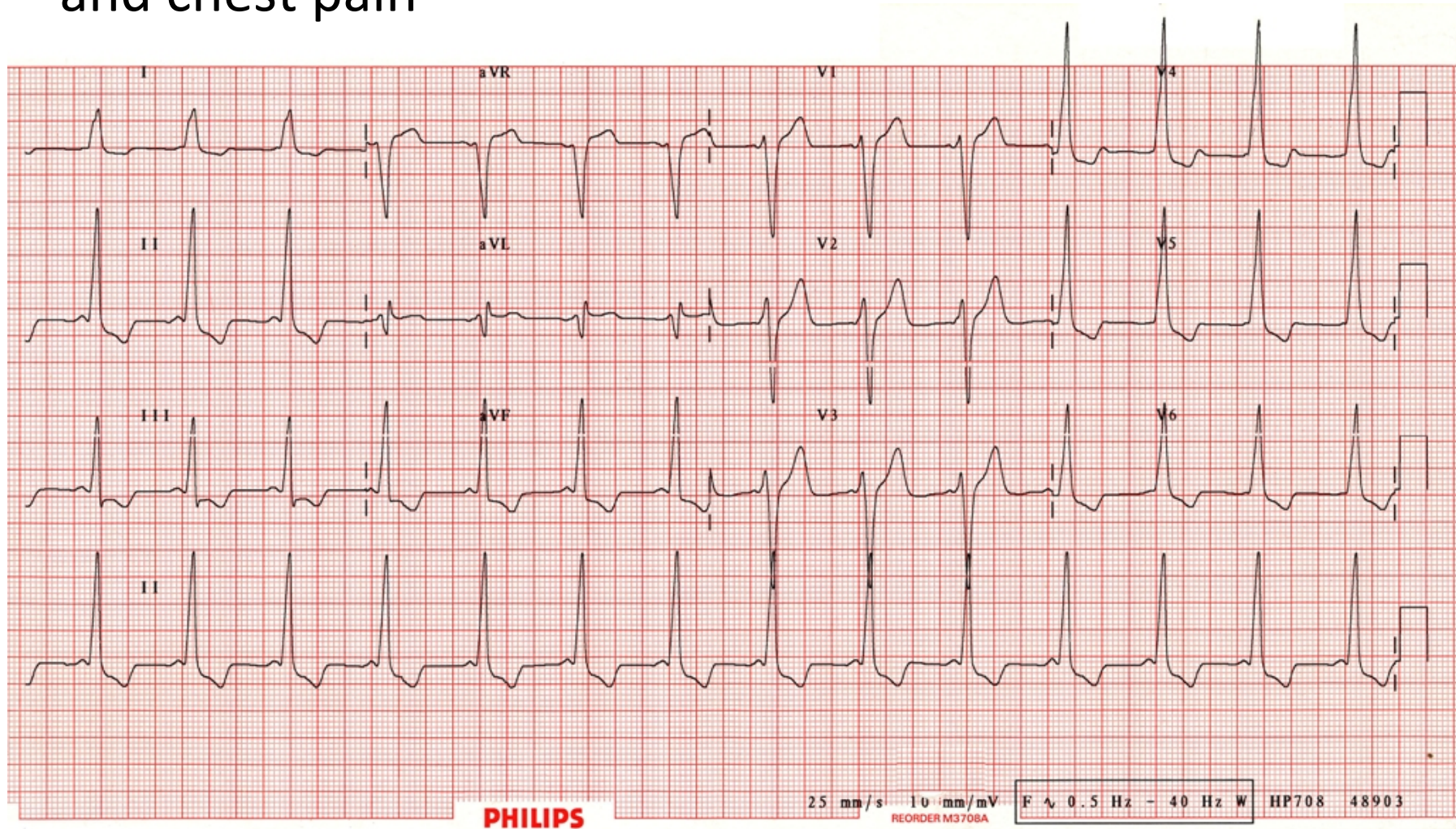
28 year old male with four hours of chest pain



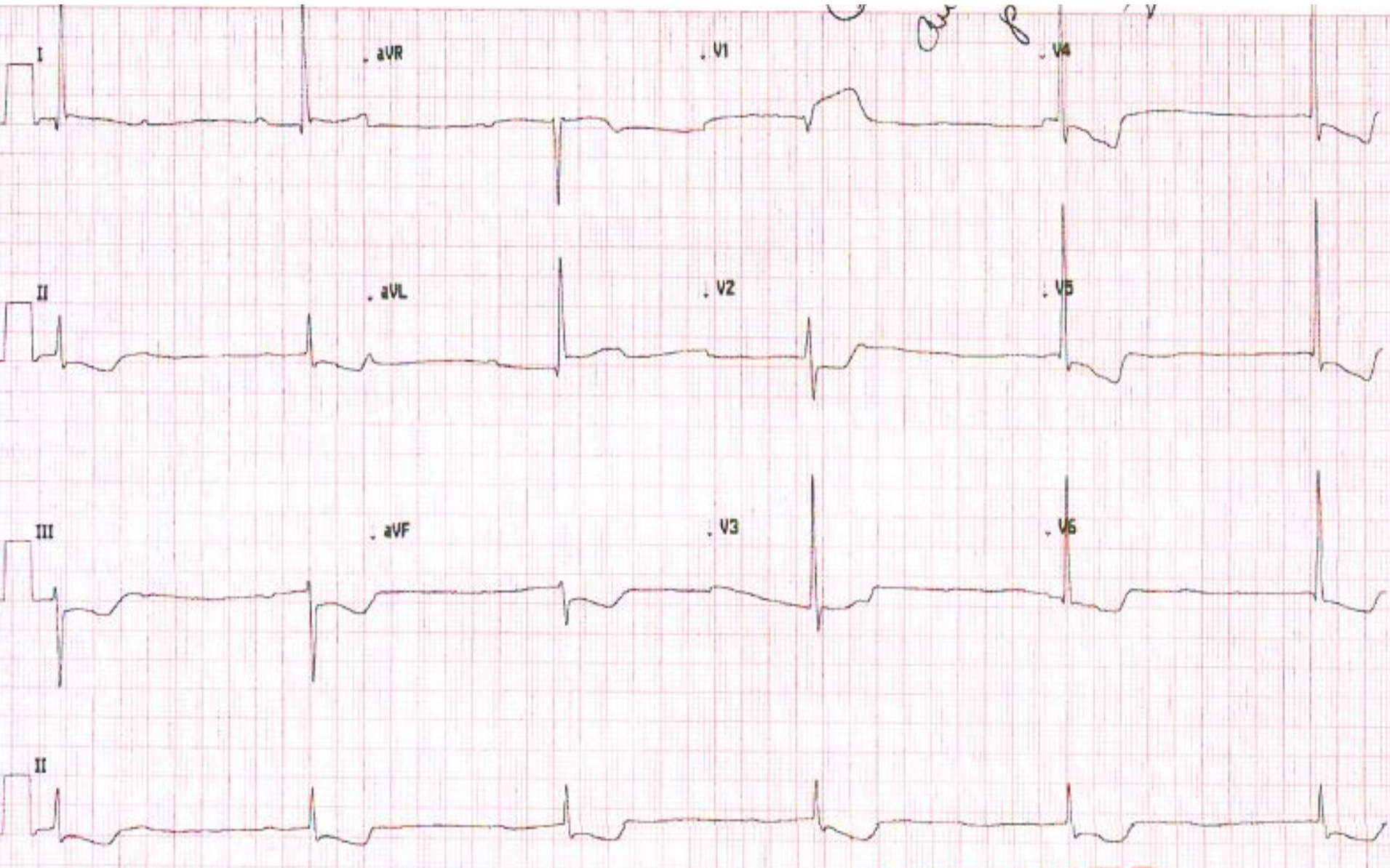
68 year old male with HTN, diabetes, presents with diaphoresis and presyncope at work. LOC en route.



24 year old male, studying for exams, palpitations and chest pain

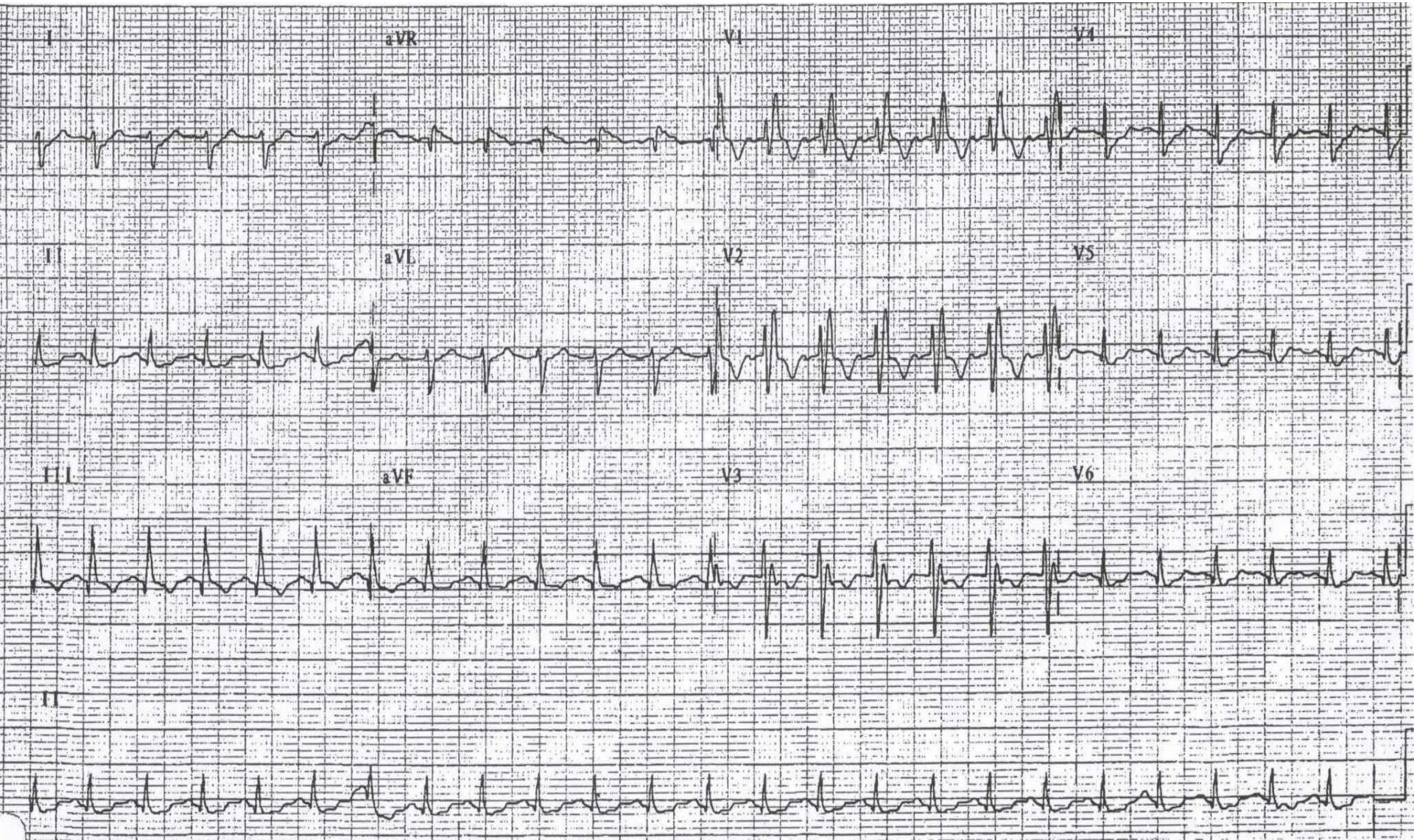


56 year old male with tobacco abuse presents with chest pain, nausea, vomiting

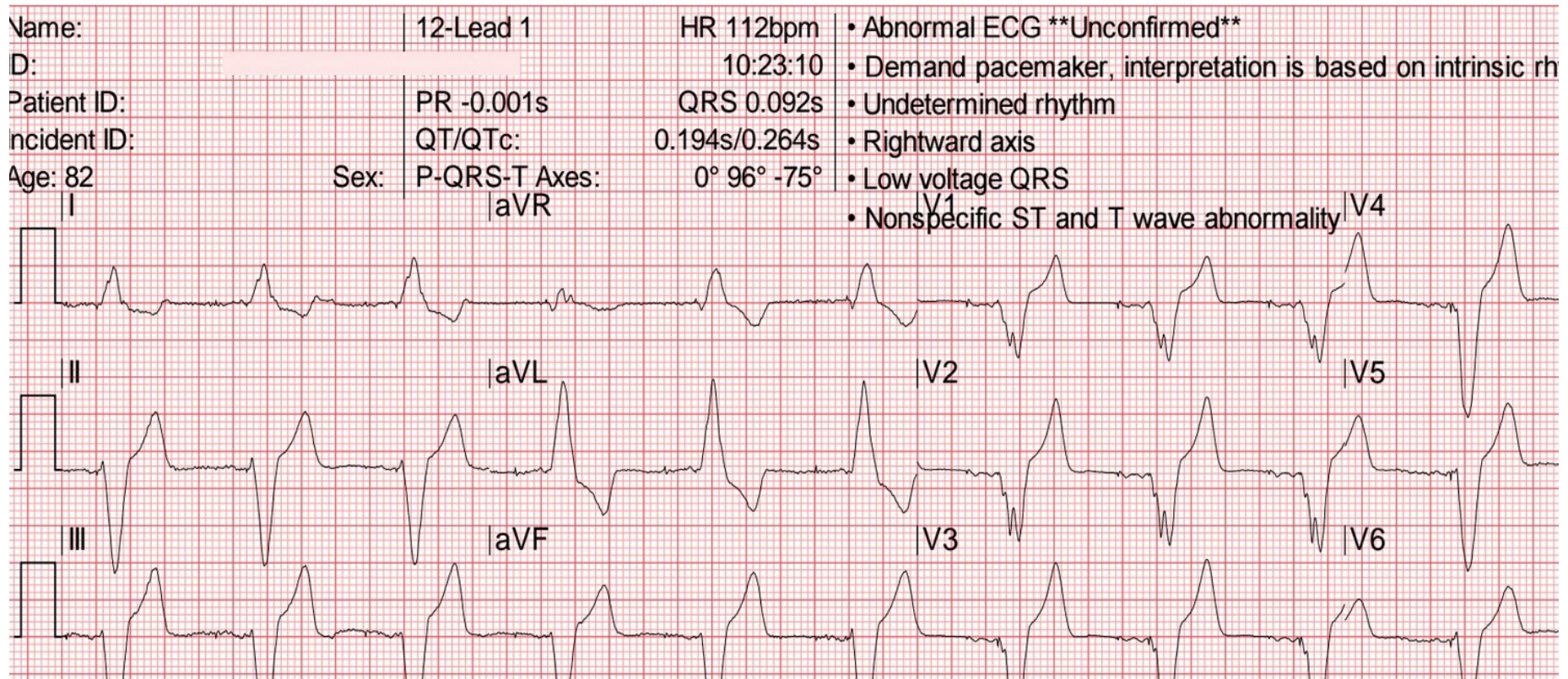


72 year old female with history of ovarian cancer
presents with shortness of breath

17

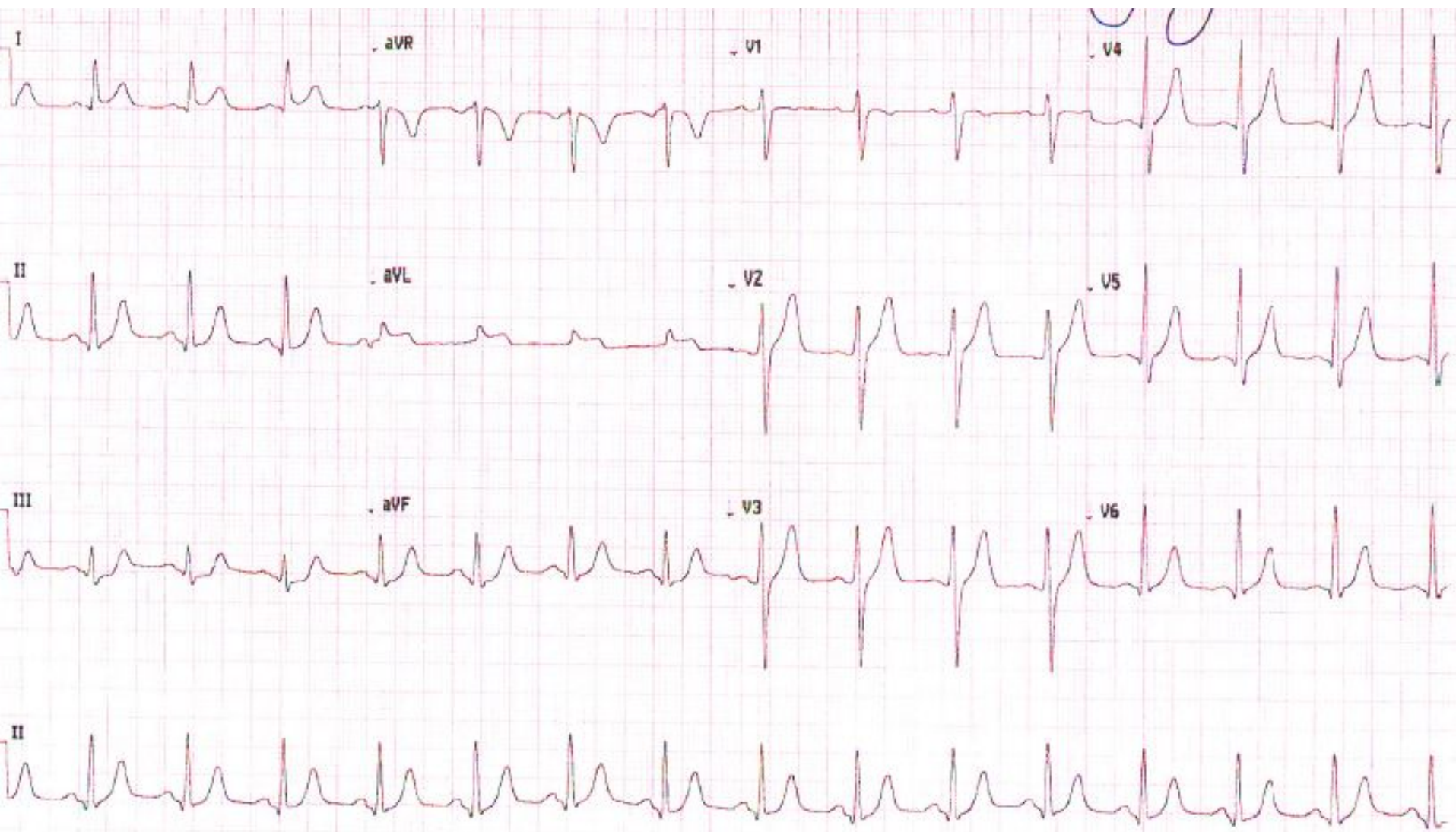


72 year old male with history of coronary artery disease, afib, defibrillator, presents to chest pain and shortness of breath



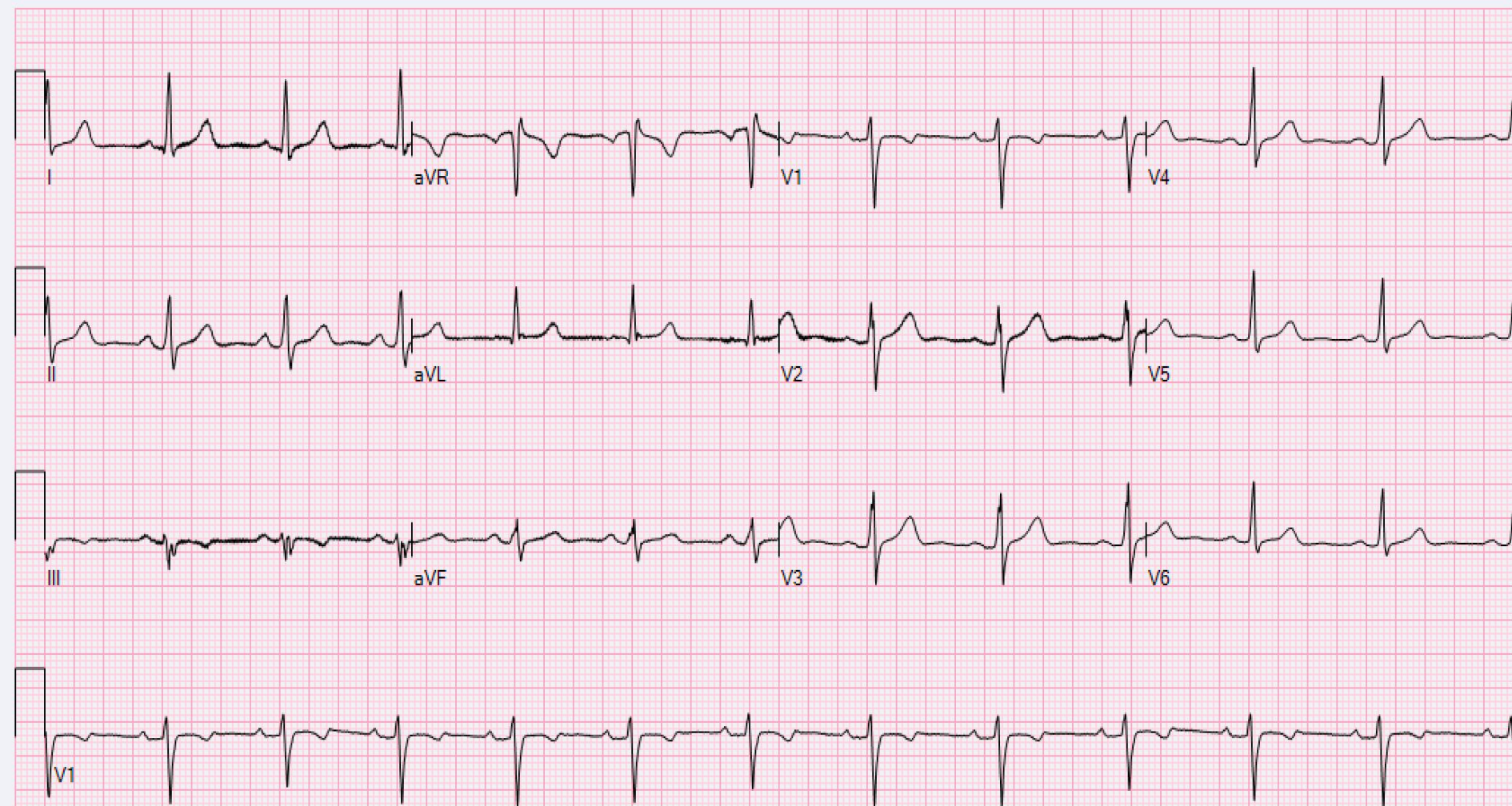
69 year old male with HTN, HLD, DM, chest pain
while tailgating before UGA game

19

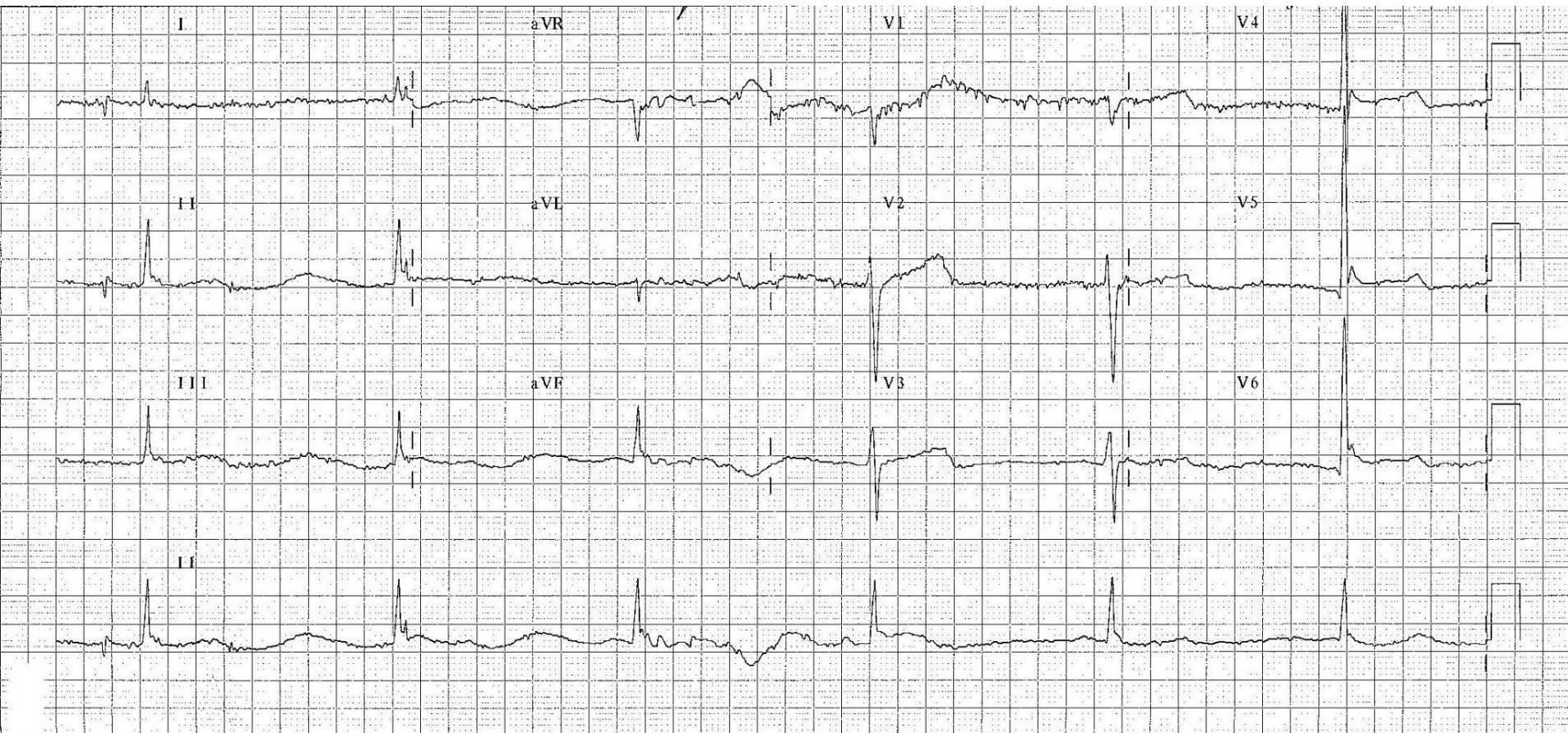


55 year old female with HTN, HLD, with neck and shoulder pain

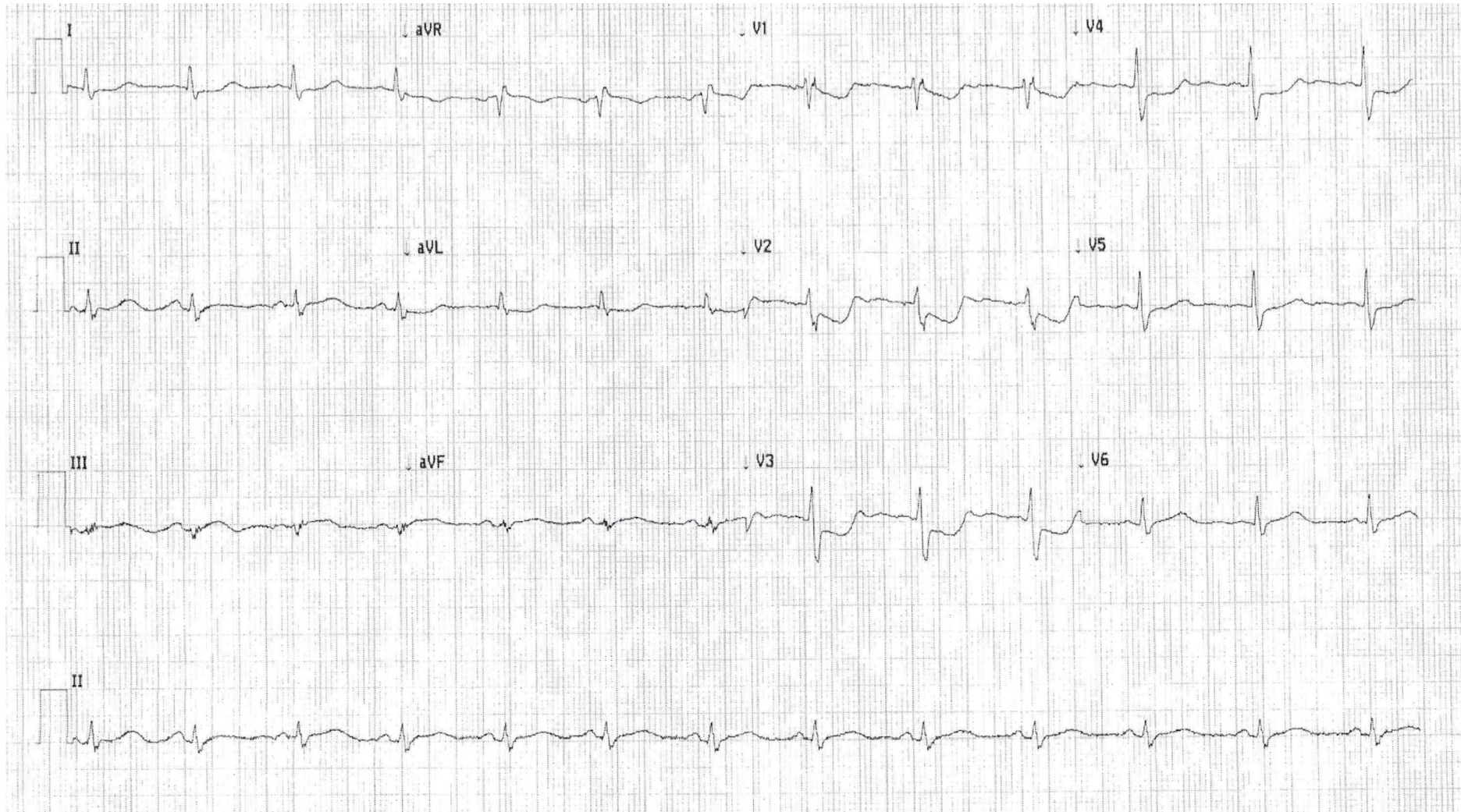
20



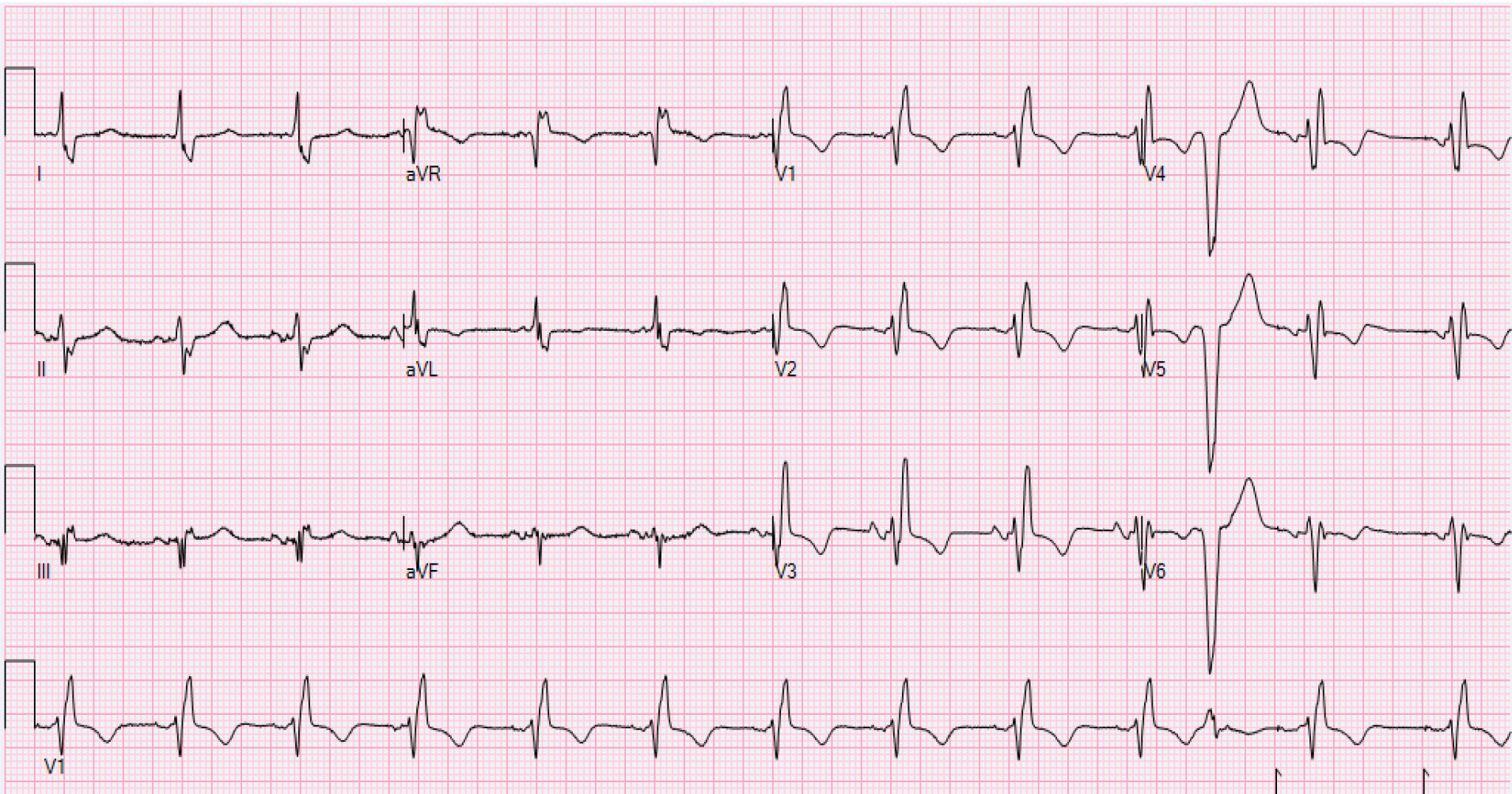
65 year old male, history of alcohol and drug use,
found altered in downtown Athens after the national
championship game 2018



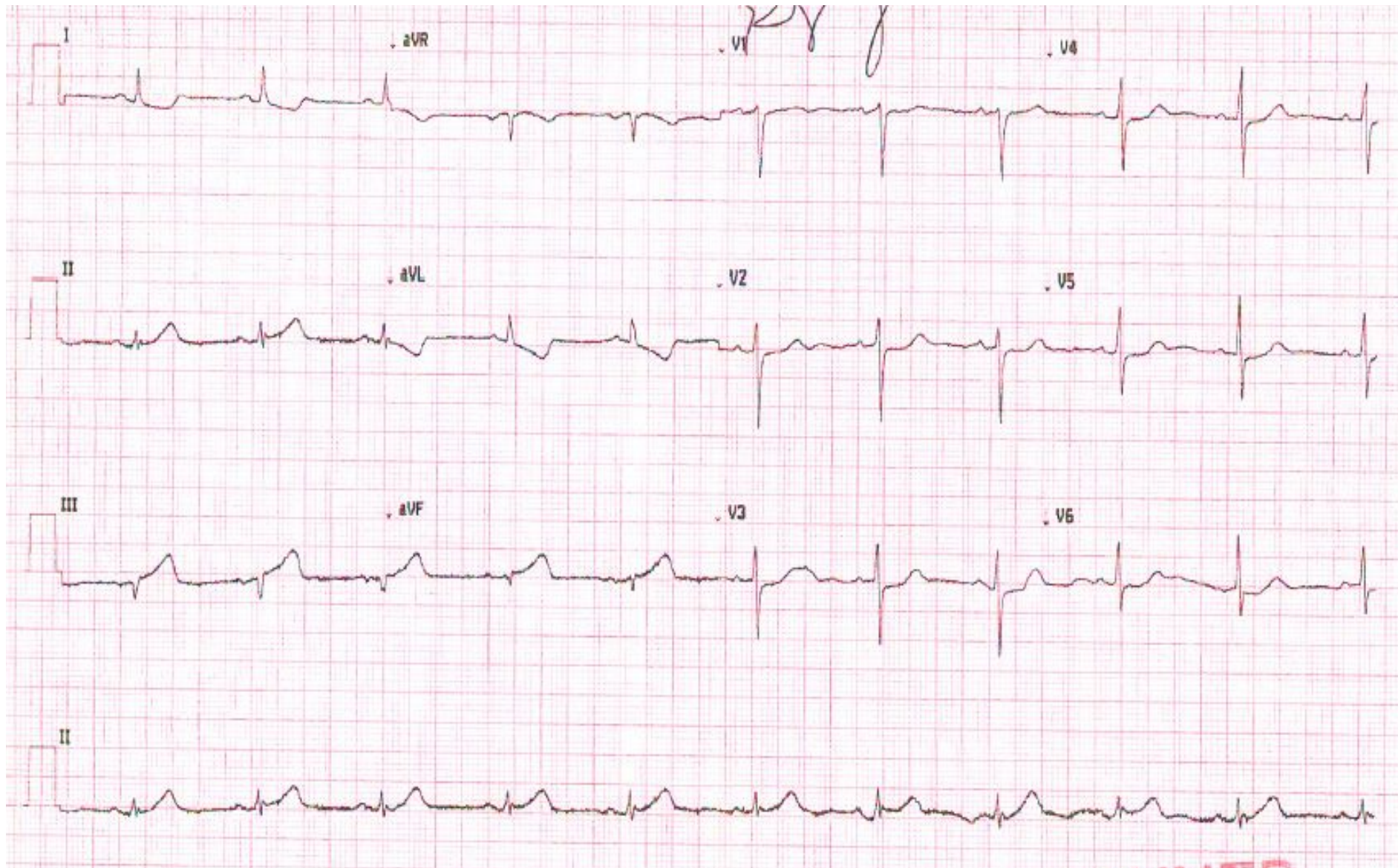
Rapid Fire EKGs



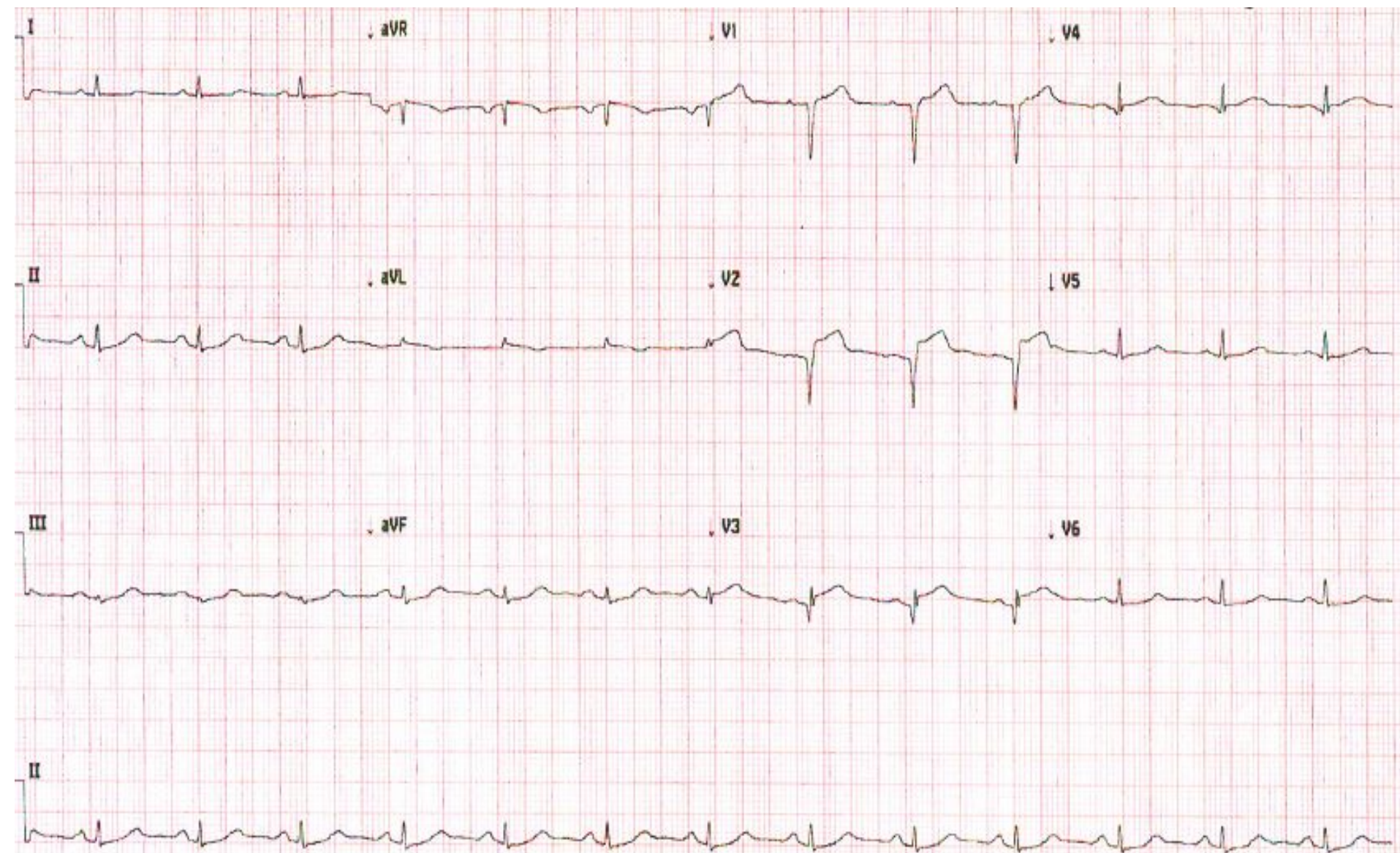
Rapid Fire EKGs



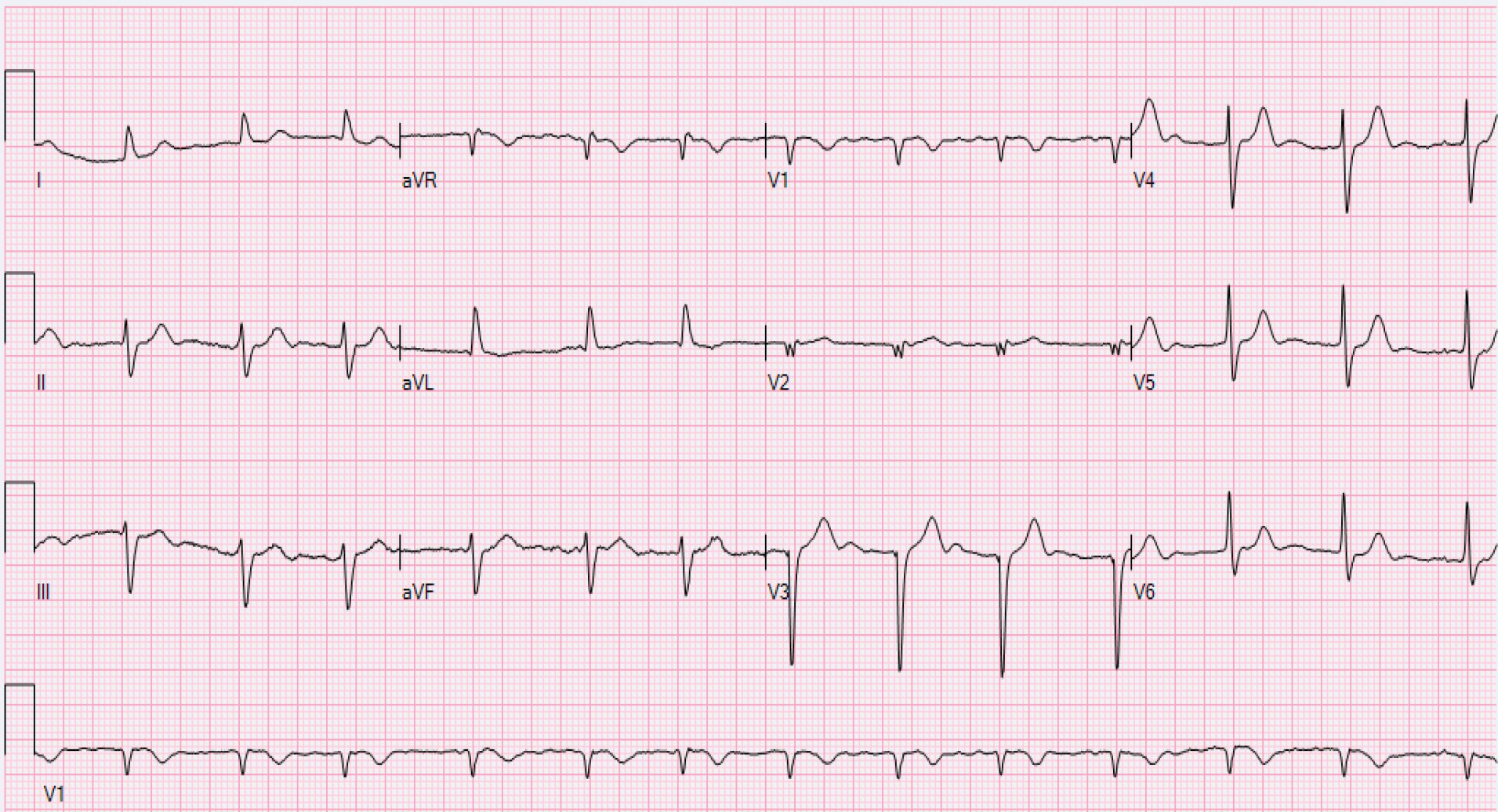
Rapid Fire EKGs



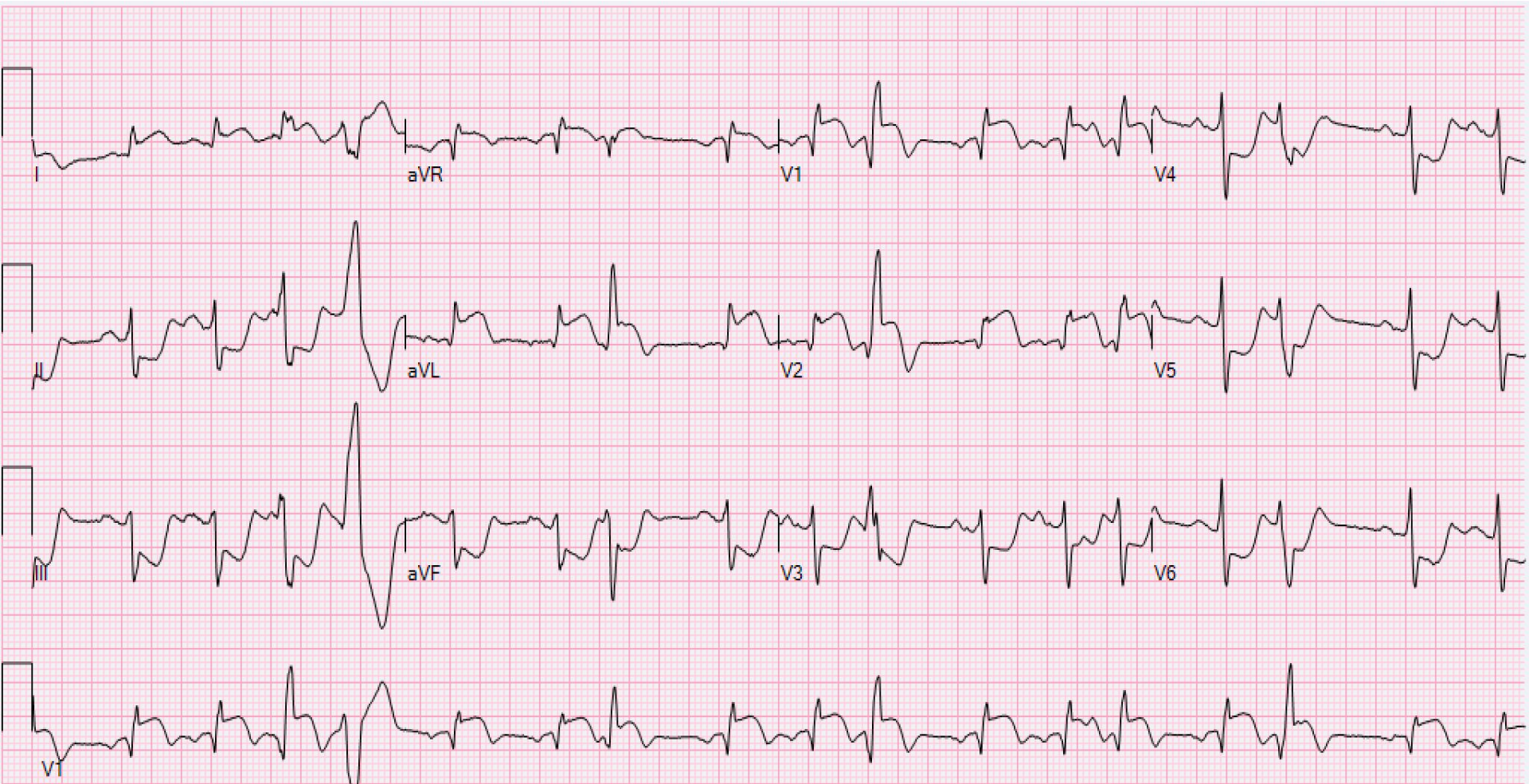
Rapid Fire EKGs



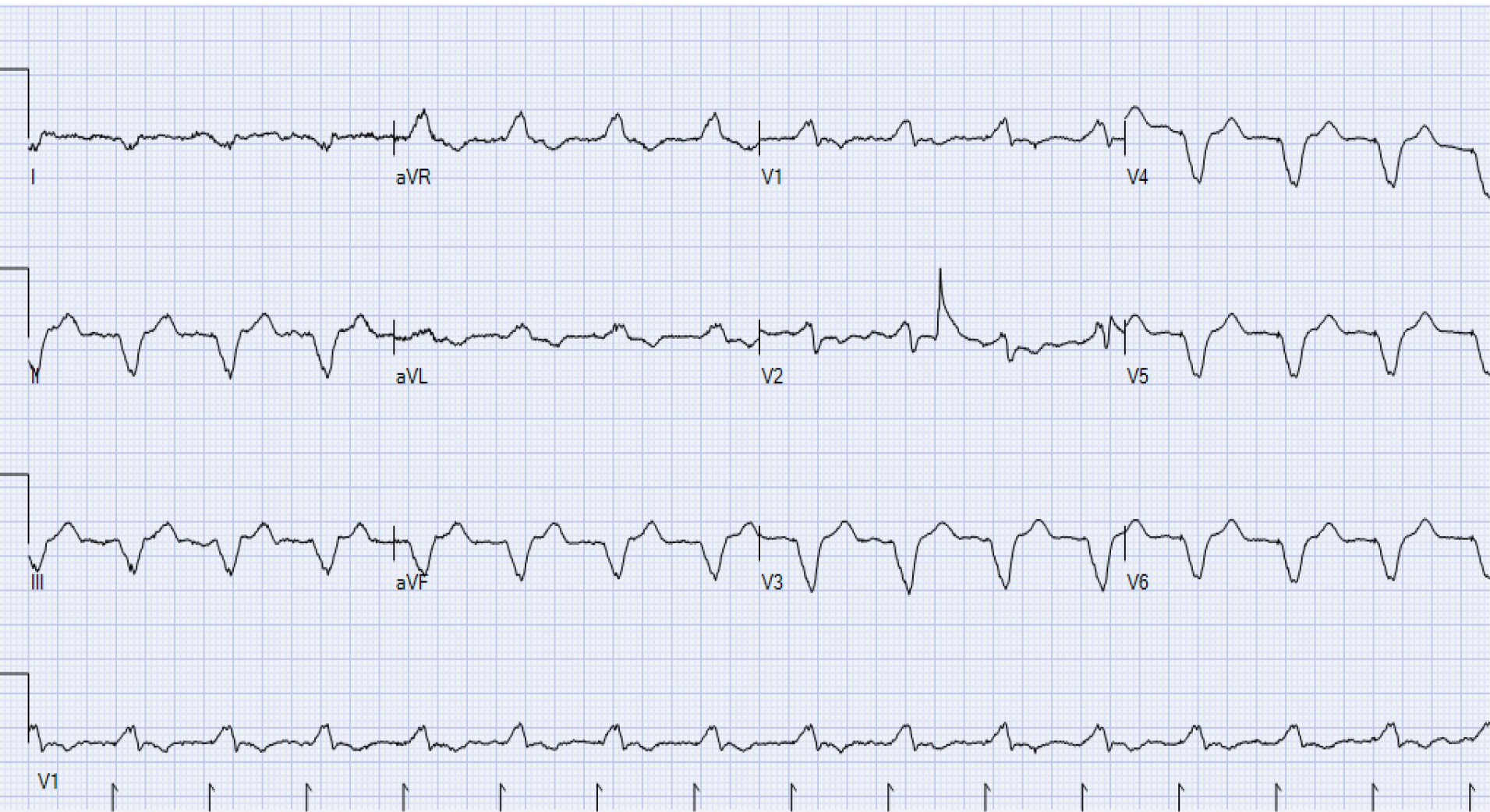Rapid Fire EKGs



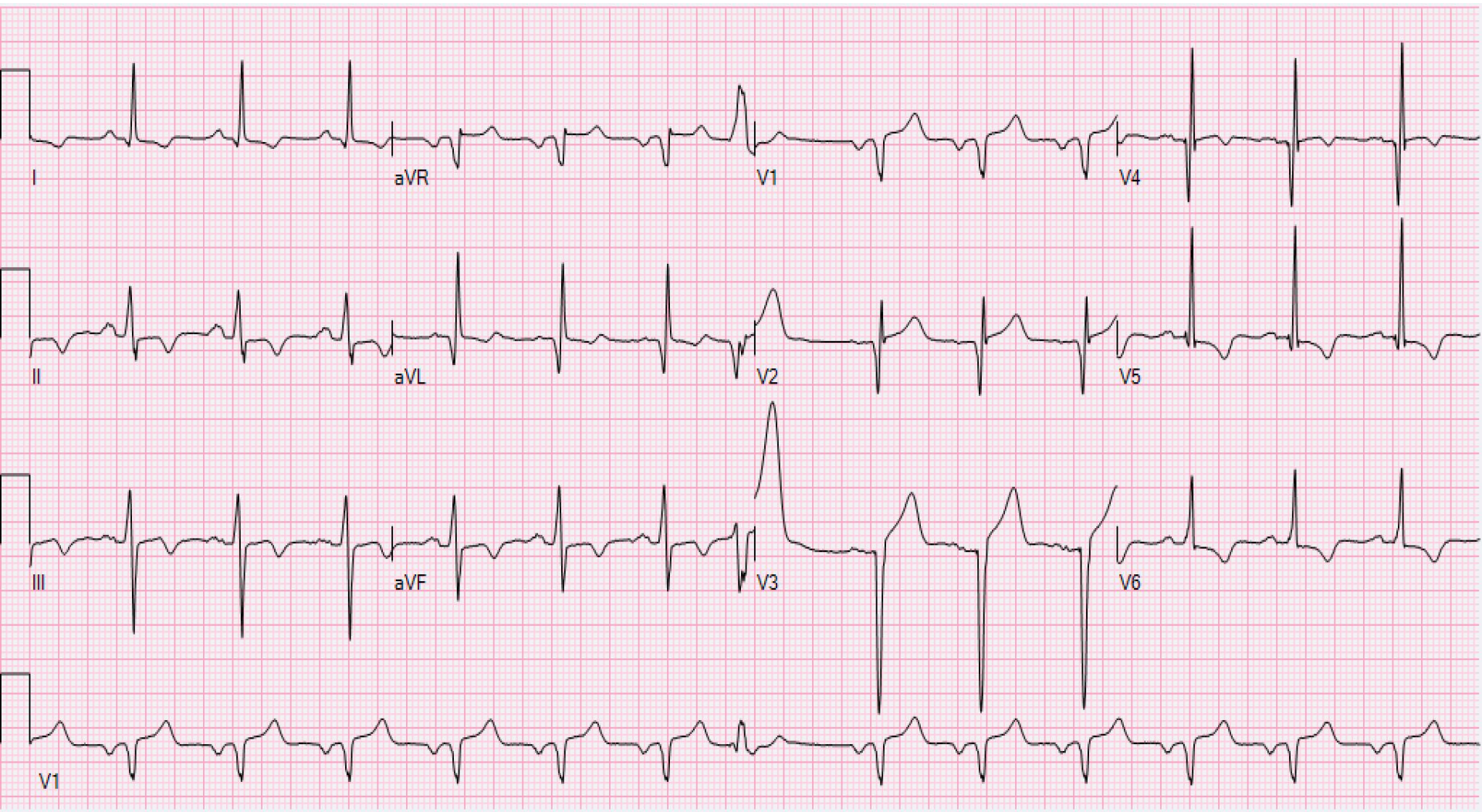
Rapid Fire EKGs



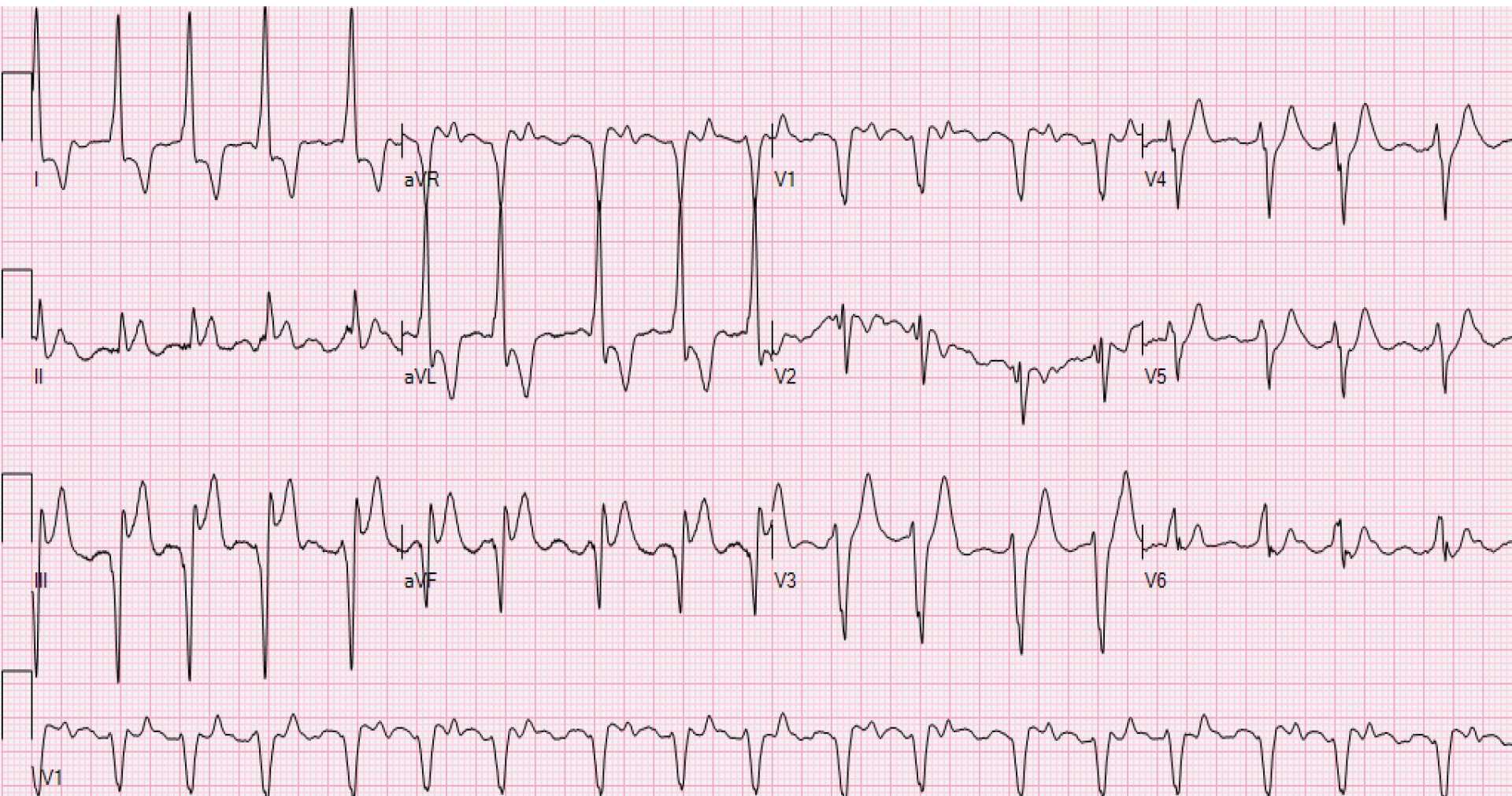
Rapid Fire EKGs



Rapid Fire EKGs



Rapid Fire EKGs



1. Inferior STEMI with posterior extension
2. Anterior STEMI
3. Lateral STEMI
4. Evolving anterior STEMI
5. Mild hyperkalemia
6. Severe hyperkalemia
7. Acute pericarditis
8. Inferior STEMI
9. LBBB anterior STEMI
10. LBBB inferior STEMI
11. LBBB, not a STEMI
12. Left ventricular hypertrophy
13. Early repolarization
14. Inferior STEMI, complete heart block
15. Wolff Parkinson White
16. Posterior STEMI
17. Pulmonary embolism
18. V-paced rhythm
19. Lateral STEMI
20. Normal ECG
21. Hypothermia
22. Posterior MI
23. Afib, RBBB
24. Inferior STEMI
25. Anterior STEMI
26. Afib, old anteroseptal MI
27. Anterior STEMI
28. V-paced rhythm
29. LVH
30. HOCM, probable inferior STEMI